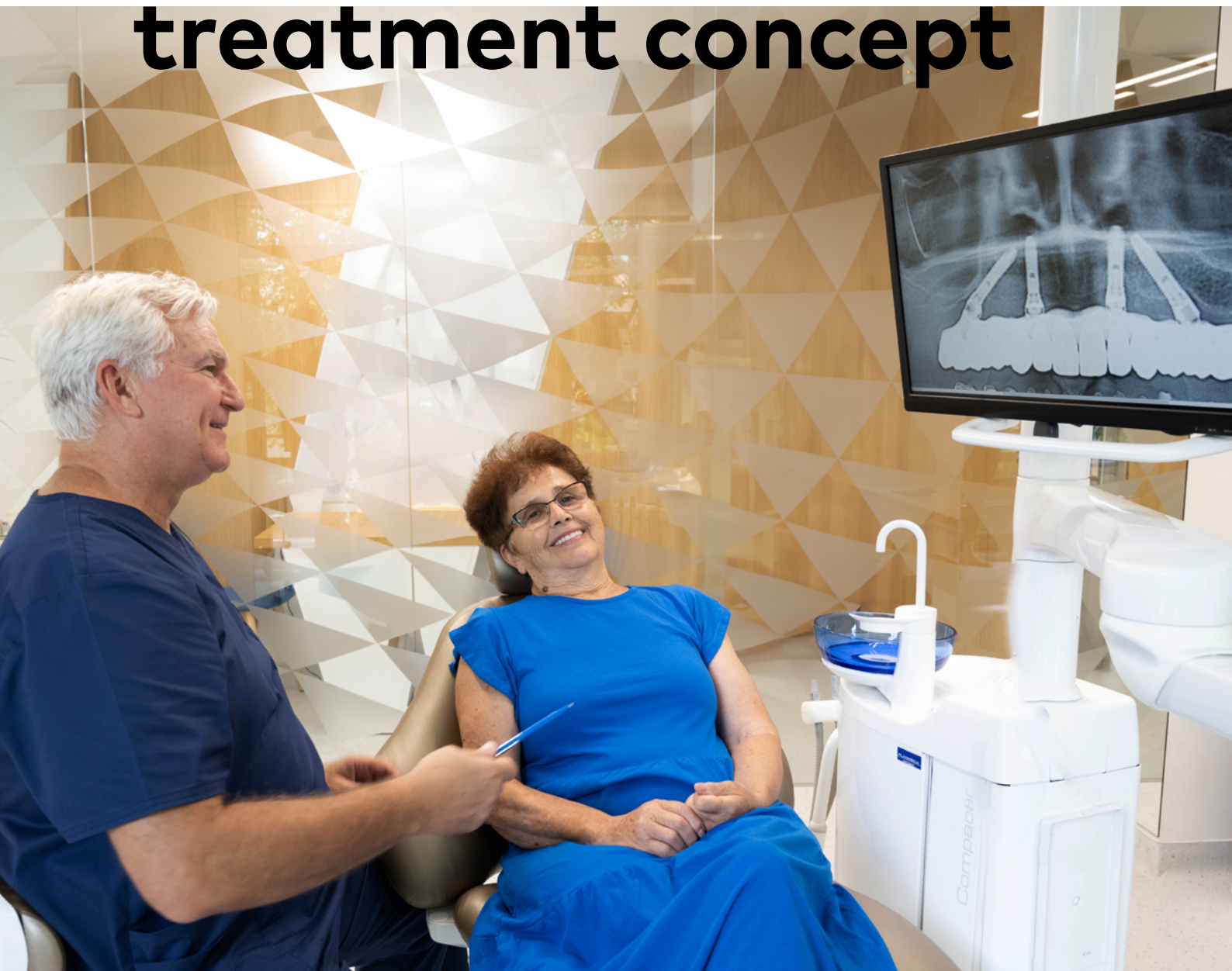

# Transforming lives with the All-on-4® treatment concept



Where patient-centric  
innovations and clinical  
science meet

Proven long-term  
success in challenging  
indications

From failing dentition  
to a confident smile,  
in one day



"I can say without exaggeration that I am a transformed individual after my All-on-4 surgery", said Lidia, who received a maxillary fixed dental prosthesis according to the All-on-4® treatment concept in 2020. At her follow-up visit in July 2023, she graciously agreed to share a photo of herself alongside her clinician, Dr. Paulo Malo, to inspire edentulous patients to choose fixed prostheses, as they can so significantly improve confidence and quality of life.

## IMPRINT

**Nobel Biocare**  
**Science First Journal**  
Volume 6, Issue 1, 2023

### **Publisher**

© 2023 Nobel Biocare AG  
Balz-Zimmermann-Strasse 7,  
8302 Kloten, Switzerland  
Tel. +41 43 211 42 00  
[science-info@nobelbiocare.com](mailto:science-info@nobelbiocare.com)

### **Editors**

Marjan Gilani, Chris Kendall,  
Diana Pop, Ewa Bednarek

### **Layout**

Hongjie Li

### **Circulation**

20,000 copies in various  
languages worldwide

### **To order a printed copy of the Science First Journal**

Please contact our customer  
service team or contact your  
sales representative.

[nobelbiocare.com/contact](https://nobelbiocare.com/contact)



**Download the  
Science First Journal**

# Celebrating 25 years of the All-on-4<sup>®</sup> treatment concept



This year, we are proudly celebrating the 25th anniversary of the All-on-4<sup>®</sup> treatment concept. This cost-efficient, graftless solution for fixed full-arch prostheses on the day of surgery, was a truly disruptive development in implantology. In 1998, Dr. Paulo Malo treated the first patient. He had spent nearly a decade developing All-on-4<sup>®</sup>—receiving valued support from the late Dr. Bo Rangert, who worked for Nobel Biocare for many years. They knew that they were pushing the boundaries but dedicated themselves to an innovation that would transform patients' lives.

Earlier this year, I had the pleasure of presenting Dr. Malo with the Quarter Century Award from Nobel Biocare. Graciously receiving the award, Dr. Malo commented: "In the early years of the All-on-4<sup>®</sup> treatment concept, very few people believed that it was possible. But I saw first-hand how successful the technique was for my patients and became completely dedicated to making it available for more people suffering from edentulism. Twenty-five years ago, it was beyond my wildest dreams that it would reach the scale that it has today."

---

***Indeed, the All-on-4<sup>®</sup> treatment concept now has 25 years of success supported by science, and its excellent performance is beyond doubt.***

---

More than 250,000 patients around the world have benefited from the original life-changing solution since it was commercially launched by Nobel Biocare in 2004. Naturally, success did not go unnoticed, and many manufacturers have since tried to copy the All-on-4<sup>®</sup> treatment concept.

We are excited to continue driving the future of the All-on-4<sup>®</sup> treatment concept, partnering with its original pioneers alongside the next generation of innovators at every step in the treatment journey, especially for cutting-edge digital workflows.

This journal features an overview of clinical cases and studies documenting the undisputed success of the All-on-4<sup>®</sup> treatment concept. It also involves interviews with skilled clinicians who share their personal insights on the protocol and how it has changed their dental practice. I hope that this will help you as a resource in knowing more about the science, techniques, and ongoing developments in treatment options from Nobel Biocare.

As we celebrate this milestone with a series of events, webinars, and training opportunities, we remain focused on the next 25 years of the All-on-4<sup>®</sup> treatment concept. Its success has proved that innovation brings the impossible to within reach.

**Patrik Eriksson**  
President Nobel Biocare

**06** "I kept going because I knew this changed the lives of patients"

Interview with Dr. Paulo Malo, Portugal

---

**18** "Whenever an innovation can improve patient outcomes, I believe we should take it into consideration"

Interview with Dr. Ana Ferro, Portugal

---

**08** Meet the experts

**22** What motivates the All-on-4® Centers of Excellence?

**10** "I will never forget my first All-on-4® treatment case"

Interview with Dr. Alexandra Marques, Portugal

---

**24** From failing dentition to a confident smile, in just one day

Dr. Roberto Sleiter, Switzerland

---

**12** "The patient was told bone harvest and grafting was the only option"

Dr. Alexandra Marques, Portugal  
Dr. Rubén Davó, Spain

---

**26** "X-Guide® has made the full-arch treatment very precise and predictable"

Interview with Dr. Marko Kamel and Katie Lank, USA

---

**14** "The key to success is adhering to surgical and prosthetic protocols"

Interview with Prof. Enrico Agliardi, Italy

**30** Multi-unit Abutments: Key to the All-on-4® treatment concept

# CONTENTS

## **32** Successful 10-year outcomes of NobelProcera® restoration in hybrid All-on-4® treatment concept

Drs. Armando Lopes and Carlos Moura Guedes, Portugal

---

## **36** A fully facial analysis-based guide to edentulous treatment

Dr. Ernest Orphanos, USA

---

## **40** Proven long-term success in challenging situations: ten-year clinical outcomes

## **42** "With proper maintenance, complex cases can still be successful"

Interview with Prof. Miguel de Araújo Nobre, Portugal

---

## **44** Where patient-centric innovations and clinical science meet

Dr. Marjan Gilani, Switzerland

# "I kept going because I knew this changed the lives of patients."



**Dr. Paulo Malo**  
Portugal

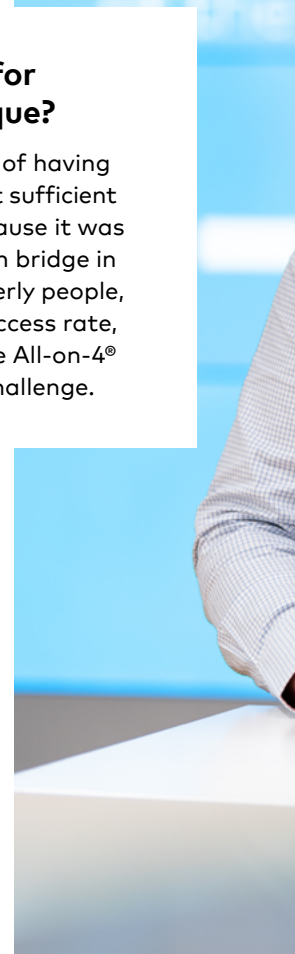The All-on-4<sup>®</sup> treatment concept is one of the most well-known techniques amongst practitioners and patients alike, for fixed full-arch restorations. First developed by Dr. Paulo Malo, we spoke with the inventor to discover more about the origins, inspirations, and challenges he faced when enabling this game-changing solution to transform the lives of hundreds of thousands lives over the past twenty-five years.

## **Dr. Malo, please tell us about the very start of developing the All-on-4<sup>®</sup> treatment concept.**

Shortly after I graduated, around 1990, I had some cases where I felt I could do immediate loading on single teeth and small bridges, and I was surprised at that time by how good the results were. One hundred percent success in fact. I got in touch with Nobel Biocare – Nobelpharma at that time – and went to Gothenburg to meet their engineer Bo Rangert. He was very impressed and wanted to have the cases published in journals, but no editor was accepting them. People were thinking this was crazy, and that the survival rate was just luck. I then started full-arch cases with the Brånemark system of five parallel implants, and immediately loading them. This was when I had the idea that if I use only four implants and inclined the posterior ones, I could place them further back, even to the molar region. This could give better support to the bridge, especially for patients with little bone.

## **What was the main motivation for pursuing a tilted implant technique?**

The development focused on the challenge of having patients, particularly elderly people, without sufficient bone in the posterior segments. This is because it was very difficult to reconstruct a fixed full-arch bridge in these cases without bone grafting. For elderly people, bone grafting does not have a very high success rate, and it complicates the treatment. I saw the All-on-4<sup>®</sup> treatment concept as the answer to this challenge.



## Who were your first patients?

The very first patient during the development phase was a close friend. An elderly man in need of mandibular treatment. It was quite an experience. I remember perfectly, calling him every day to know if everything was OK. The first maxillary case was three years later, but even though I had already done dozens of cases with this technique in the mandible, I was much more nervous in the first maxilla case. Because of the anatomy and bone density, it was far more complex.

With the first patients, we always told them that this treatment was new. But when we said the alternative is bone grafting, they immediately chose All-on-4®. It is the simplicity of the technique that makes it so great. We spent thirty minutes to an hour in surgery, placed the teeth a couple of hours later, and when patients saw it they just burst into tears. Some were the toughest of men, used to toughness in life, who you think never cried in their lives. As clinicians, without doubt, it gives you goosebumps.



## You were clearly getting a great response from the patients. What about the dental industry?

It was not at all accepted. We faced a lot of problems, and people were calling us cheaters and cowboys. People said we couldn't place just four implants or incline implants. I remember once we did a live surgery, and someone said that we must have cheated on the video because it was not possible to do it in thirty-five minutes. But it was not the opinions of dentists that I cared about; I kept going because I knew this changed the lives of patients. I did have some people that really supported me a lot, especially engineer Bo Rangert. He set up a meeting with P-I Brånemark to present my immediate loading cases; even though Brånemark disagreed with immediate loading, it was his view that people must accept it if scientific evidence exists and that it should be published. Scientific journals still would not accept my work, but with Brånemark's intervention the cases were published in Nobel Biocare's "Talk of the Times" magazine.

## What was Nobel Biocare's role in this story?

The success of the All-on-4® treatment concept would not have been possible without Nobel Biocare. You can come up with the best ideas, but if you cannot communicate them, they are of little worth. I had been knocking on the door of implant companies for a long time, and nobody was accepting it. When a new CEO took over at Nobel Biocare in 2001, Bo Rangert saw an opportunity so he arranged a meeting. I visited the CEO's office to present the concept, she asked his opinion, and he explained the success he had been seeing for several years, and the benefits it brought to the patients – the simplicity, the Immediate Function, no bone grafting. Nobel Biocare agreed to take it on, despite the criticism, and we have worked together ever since. The surgical protocol has basically remained the same, but we have continued innovating the top-quality products to achieve the best results.

## Did you expect to see the concept become so successful?

Not in my wildest dreams did I expect it to become so big. I knew that it was clinically successful, especially after I saw the results in the maxilla. But it was a disruptive technique. Like anything we do in life, few people accept disruption immediately. When you cannot convince people of something you know is successful, you feel the pressure and sometimes you lose the energy. But you get up the next morning, and you continue the mission.

# Meet



**Dr. Julie Erica Schlosser**  
Denmark



**Dr. Glen Liddelow**  
Australia



**Dr. Robert Bowe**  
Ireland

## Develop your practice

Initially, we didn't expect that the All-on-4<sup>®</sup> treatment concept would have much impact on our clinic as we did not treat many edentulous patients.

The All-on-4<sup>®</sup> treatment concept opened opportunities for us and technicians to offer an immediate fixed solution to patients who couldn't live with removable prostheses, and we began receiving many more referrals as a result.

## True Immediate Function

I have been using Nobel Biocare implants in immediate loading for almost 30 years, and the All-on-4<sup>®</sup> protocol for the last 20 years. I know these products and procedures have been refined over decades for immediate loading, to optimize rehabilitation for our patients. Furthermore, they are validated by long-term scientific research to consistently achieve sufficient initial stability, high bone-to-implant contact, and lasting osseointegration.

## Patient centricity

By involving patients in decision-making and prioritizing their desired experience and outcomes over everything else, we ensure they stay compliant and reduce the risks of complications. This is even more important after advanced surgical solutions like the All-on-4<sup>®</sup> treatment concept. Partnership with Nobel Biocare and using their premium solutions also give me the confidence that I am offering my patients the care and outcomes they hope for.



# the experts



**Dr. Ana Ferro**  
Portugal

## Surface science makes a difference

The goal of the All-on-4® treatment concept is to improve the quality of life of more patients, with both immediate and long-term success.

I consider the new Xeal™ and TiUltra™ anodized surfaces a major breakthrough. We observe low marginal bone remodeling and excellent soft tissue health, which is essential for the abutment-level prosthesis of this concept.



**Dr. Dennis Rohner**  
Switzerland

## Digital is the future

Treating edentulous or partially edentulous patients with the All-on-4® protocol in a single session requires meticulous preparation and digital planning on the one hand, and straightforward and precise implementation during surgery on the other. To further increase patient safety and accuracy of the implementation of the planned surgery, X-Guide® navigation has become an increasingly important means to us, not only for All-on-4®, but also for single implant treatment.



**CDT. Sean Han**  
United States

## A flexible strategy

Nobel Biocare's Multi-unit Abutments provide restorative flexibility by allowing angulation correction and individualized emergence profile design. This enables optimal placement of the implant and natural-looking esthetics, and great function of the final restoration.

Additionally, it offers a range of prosthetic components for various implant diameters and heights, allowing for versatility in treatment planning.

# "I will never forget my first All-on-4<sup>®</sup> treatment case."



**Dr. Alexandra Marques**  
Portugal

**While the gender diversity of dental school enrollment is increasing<sup>1</sup>, female representation among dental thought leaders still lags behind that of their male counterparts. We asked Dr. Alexandra Marques, a member of the FOR Emerging Leader Program to tell us about this program and women in advanced surgeries.**

## **Dr. Marques, when did you decide to become a maxillofacial surgeon?**

Everything started during my time in medical school, where my fascination with jaws, teeth, and the ability of dentists to transform individuals by restoring their smiles, took hold. Becoming an oral surgeon gives you the power to achieve fast and powerful results. I will never forget my first All-on-4<sup>®</sup> case, and the experience of seeing a patient shedding tears of joy when she looked in the mirror for the first time immediately after the surgery.

## **Why did you decide to join the FOR Emerging Leader Program?**

During my career, I have worked with many speakers and advanced surgeons around the world, completed international degrees, and built up my own large clinic. But something was missing until I came across the information about the FOR Emerging Leaders Program. Everything it offered made sense; the coaching, the networking, the training and workshops on how to master on-stage and online lecturing and clinical presentations, and the possibility to connect and exchange experiences with advanced clinicians from all over the world. I applied, and I received an unexpected call one day informing me of being accepted into the ELP program.



**The FOR Emerging Leader Program**

### **Reference**

1. Fleming E, et al. Community Dent Oral Epidemiol. 2023 ;51(3):365-372

## How do female graduates from dental schools compare to their male counterparts?

Even if the number of women in medical and dental schools has increased in recent years, still we see a big gap when we look at key opinion leaders who perform advanced surgeries, and speakers at large conferences. It seems women prefer Ortho or Pediatrics, while maxillofacial surgery remains a male-dominated field. Every time I attend a course about "heavy surgery", I find myself most of the time as the only woman. This includes most courses about All-on-4® or placing zygomatic implants.

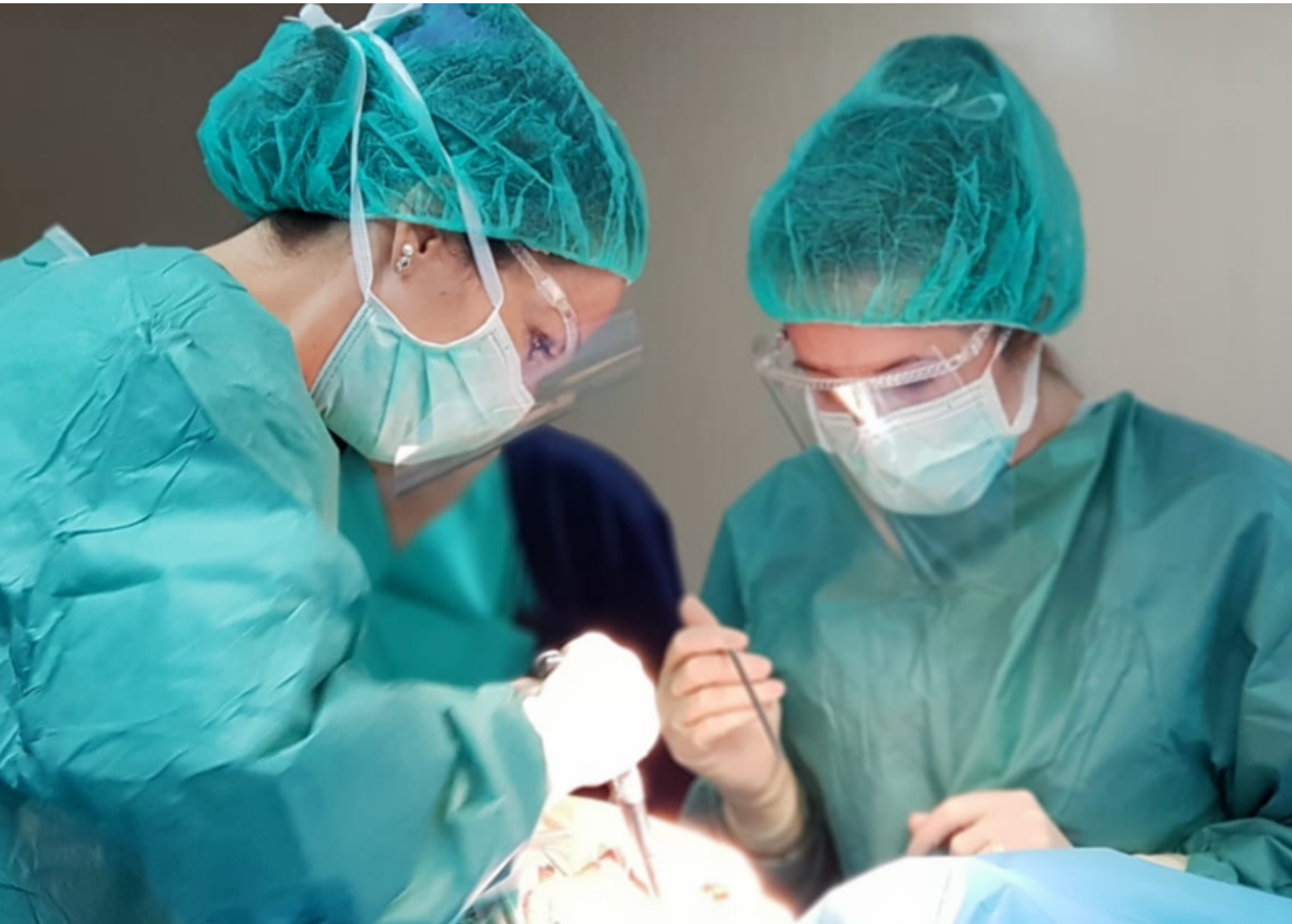## What can women do to close this gap?

It is important that they believe in their skills and in their capacity, to assert their own unique perspectives and contributions and build a strong career.

## Is there anything that the industry can do to inspire and engage young female dentists?

The industry can build more support programs to improve capacities of the young dentist and help them build their careers. This can be as simple as dedicating an All-on-4® course to female clinicians. It can also engage more female clinicians as speakers and trainers, to benefit from the diversity and the great work of strong and successful mentors such as my colleagues Ana Ferro and Edith Groenendijk of the FOR Emerging Leader Council. This will definitely inspire the younger generation.

The future depends on what we do in the present.



"The industry can build more support programs to improve capacities of the young dentist."

# "The patient was told bone harvest and grafting was the only option."



**Dr. Alexandra Marques**  
Portugal



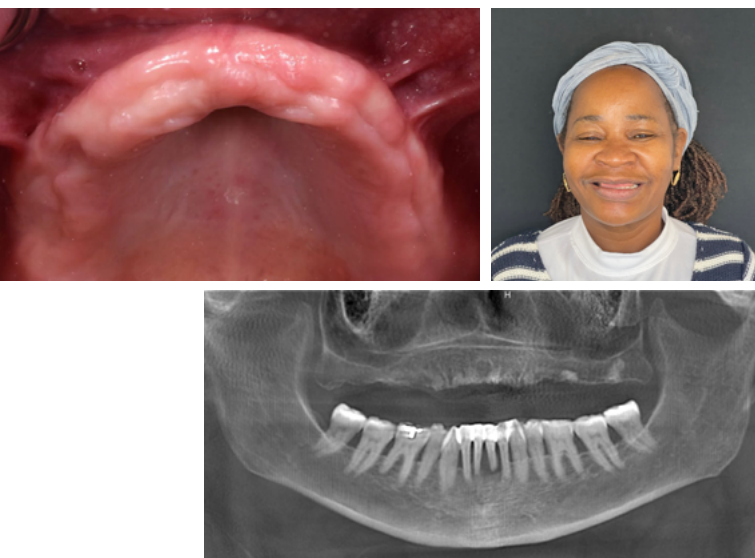**Dr. Rubén Davó**  
Spain

## Clinical situation

Francisca began losing her teeth at the young age of nine. She grew up in Angola, where access to dental care was very limited at the time. Her dental problems persisted, leading her to extract more of her maxillary teeth over time. At the age of 19, she was advised by the local dentist that if she extracts all the maxillary teeth, including the anterior ones that were still functional, she could have a removable denture with white and aligned teeth, which she did.

"It was the biggest mistake of my life," she says. The removable denture did not work due to the progressive atrophy in her maxilla. Even after five adjustments and changing the denture, the retention was never adequate, robbing her of her confidence to smile.

When Francisca relocated to Portugal, she consulted with several dentists who recommended extensive and invasive surgeries, bone harvesting, and grafting. She continued to live without a maxillary denture for an entire year until she visited MD Clínica. Upon hearing the suggestion that she could have a fixed denture in just 24 hours, her immediate response was an enthusiastic "Façamos isso!" - which translates to "let's do this!"



Periodontal examination and face analysis prior to surgery.



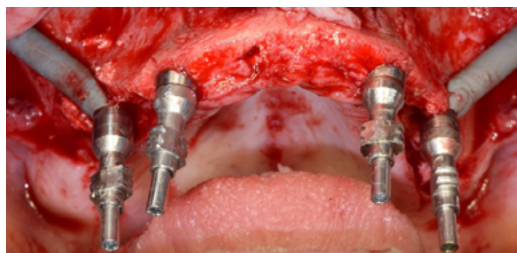
Treatment of the severely atrophic maxilla.  
Dr. Ruben Davo

## Surgical solution

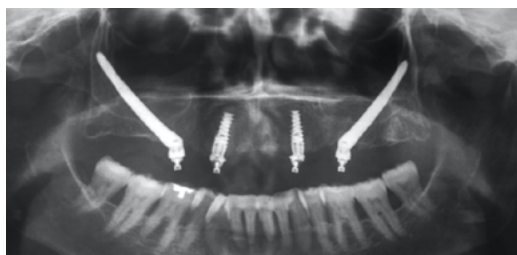
Dr. Rubén Davó and I collaborated on Francisca's surgery. Our clinical and X-ray image analyses showed alveolar bone atrophy, with severe thickness loss, in addition to a high-level pneumatization of the maxillary sinus, bilaterally, and history of implant loss. We are dedicated to providing our patients with the best possible outcome, which is why we have carefully selected the most effective and reliable implants and prostheses for Francisca's surgery. We chose the hybrid All-on-4® treatment concept.<sup>1</sup>

For the posterior implant, we used NobelZygoma 45°. This implant has a unique design, featuring a tapered tip that makes insertion easier and facilitates primary stability for Immediate Function. Moreover, the implant body is partially unthreaded at the coronal part, which interfaces with the soft tissue and does not necessarily engage with the bone.

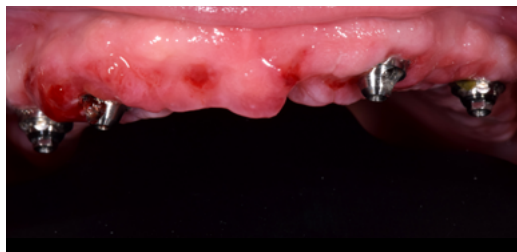Studies have shown that the NobelZygoma implant offers a high survival rate and low rate of complications, making it a viable option for graftless restoration of the maxilla, including immediate loading protocols.<sup>2</sup> We also used NobelActive® in the anterior, and NobelProcera® implant-supported prosthesis with immediate loading.



Preparation for impression coping after implant insertion.



Orthopantomogram after placing the straight and angled Multi-unit Abutments.



Healthy soft tissue after healing.

## Patient outcomes

Before the treatment, Francisca faced a range of physical, social, and emotional challenges due to her condition. But she was able to return to her normal activities and felt more confident in social situations after the treatment. One month after her surgery, Francisca attended her daughter's wedding and sent us a photo with the caption, 'Now I can truly smile.'



Patient smile after delivery of the final NobelProcera prosthesis.

### Reference

1. Lopes A, et al. J Clin Med. 2021 16;10(16):3600.
2. Davó R, et al. J Clin Med. 2020 9;9(2):480.

# "The key to success is adhering to surgical and prosthetic protocols."



**Prof. Enrico Agliardi**  
Italy

With many years of experience in oral, orthognathic, pre-prosthetic, and pre-implant surgery and advanced implantology, with both intraoral and extraoral implants, Prof. Enrico Agliardi is a prolific author and active participant in various national and international congresses, where he shares his expertise and helps advance the field of dentistry.

**Prof. Agliardi, you are well-known for advanced maxillofacial surgeries, especially for edentulous patients. When do you choose to use the All-on-4® treatment concept?**

As a maxillofacial surgeon, I did a lot of bone grafting at the beginning of my career and I still do in selected cases. I saw how complicated it was and how high the biological and financial costs are for the patient and the clinician. In addition, and after several years of academic and clinical experience, I have learned that in grafts, residual bone – even if atrophic – plays a key role. The All-on-4® treatment concept makes the most of residual bone.

It allows me to drastically reduce the use of grafts. I use this technique for more than 70% of my edentulous patients, as it is less demanding for both the patient and the clinician. For the others, I use V-II-V in 25% of cases, and zygomatic implants or grafting in 5%.

For decision-making, I first check the residual bone availability. This ranges from full bone volume adequate to place straight implants, to complete alveolar bone resorption, for which I use four zygomatic implants. In fact, some modifications to the original protocol, such as V-II-V trans-sinus or trans-crestal implants have made it possible to extend the use of the All-on-4® treatment concept in a large majority of edentulous patients.

## You have recently published a clinical study about full-arch treatment with up to 17 years of follow-up<sup>1</sup>. What were the main outcomes of this study?

I started using the All-on-4<sup>®</sup> protocol in my private practice in 2004, so I could follow an original pool of 173 patients treated from April 2004 until January 2009, with 692 implants (72 maxillary and 101 mandibular arches). The majority of patients were scheduled for regular recall appointments, so I was able to collect data on bone loss and any complications. Some drop out occurred, as expected.

At up to 17 years of function, implant survival rates were 97.5% in the maxilla and 96.9% in the mandible, with no difference between axial and tilted implants. We used statistical models to analyze the relationship between implant failure and potential risk indicators. Only diabetes type 2 was very close to significance, where age at the time of surgery, gender, arch, smoking or history of periodontal disease were not contributing factors.

We also used peri-apical radiography to calculate marginal bone loss. At 10 years, it was 1.70 mm in the maxilla and 1.80 mm in the mandible. Also, the difference in marginal bone loss between axial and tilted implants was not significant after 10 years in the maxilla, while it was in the mandible. Moreover, bone loss was more pronounced in the mandible at both 5 and 10-year follow-ups. Statistical analysis showed a correlation between arch and bone loss, while no correlation was found with age, gender, smoking, diabetes, and history of periodontal disease.

### Reference

1. Agliardi EL, et al. Clin Oral Implants Res. 2023 ;34(4):351-366

## Does the choice of the implant system and its premium design contribute to the predictability of the outcome?

I have been using Nobel Biocare implants for all my dental rehabilitation procedures, and I strongly believe that this choice has greatly contributed to the success of my treatments. As many as 80% of my patients present with complex initial conditions, including advanced bone atrophy, failed prior implant treatments, or poor bone quality, and are often referred to me by other patients or colleagues. I frequently encounter a limited amount of residual bone with poor density, requiring an implant that can provide secure anchorage without compromising the bone. With a wide range of implant morphologies and dimensions, Nobel Biocare offers a diverse portfolio of products, backed by substantial investment in research and development and close collaboration with global experts and opinion leaders.

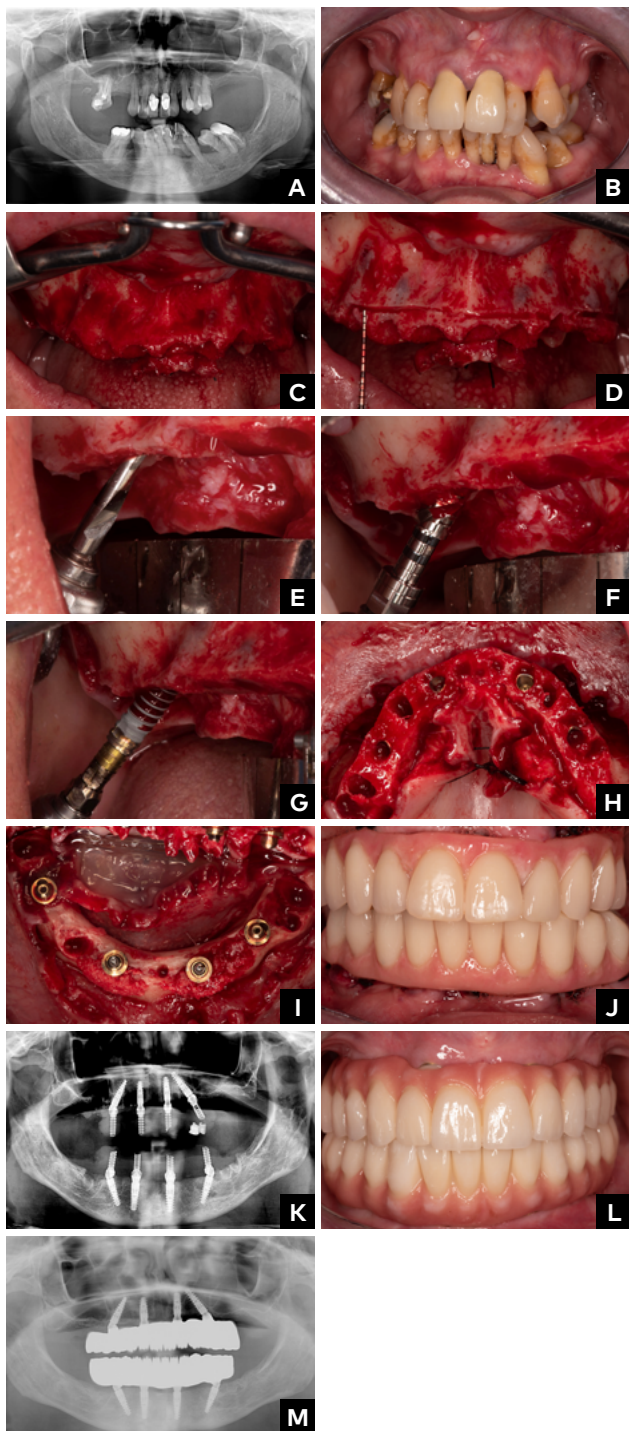
---

*"With a wide range of implant morphologies and dimensions, Nobel Biocare offers a diverse portfolio of products, backed by substantial investment in research and development and close collaboration with global experts and opinion leaders."*

---



Read the open access article



**A/B** Pre-operative X-ray and intraoral pre-operative frontal view. Residual teeth show severe periodontitis and compromised restorations. **C/D** Flap elevation, bone exposure and ridge regularization taking into consideration the amount of bone reduction needed to address the gummy smile. **E/F/G** Pilot osteotomy with OsseoDirector pilot drill. Final osteotomy with OsseoShaper 1, and placement of Nobel Biocare N1 Implant. **H** Occlusal view after insertion in the maxilla. **I** Occlusal view after implant insertion and placement of the Multi-unit Abutments Xeal in the mandible. **J** Provisional prosthesis delivered immediately after surgery. **K** X-ray immediately after surgery. **L** Final prosthesis 6 months after surgery. **M** X-ray 8 months after surgery.

## Have you used the Nobel Biocare N1™ implant system in an All-on-4® case?

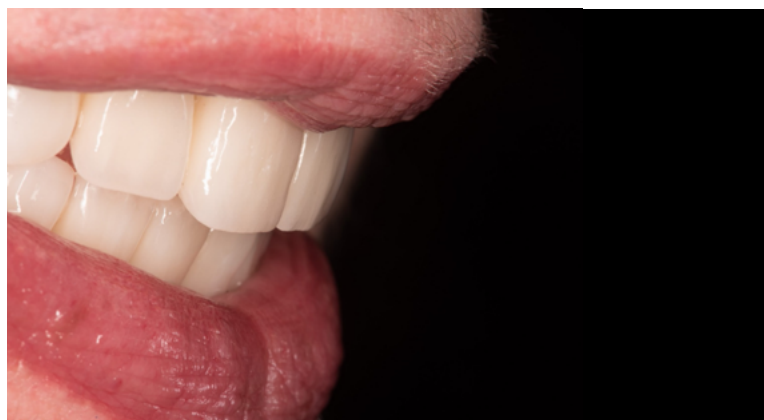Back in 2019, I decided to test the new implant system in a challenging situation (fig A-N). Because of the gummy smile, a major osteotomy was necessary to level the crestal cortical bone. In this context, achieving good primary stability with most conventional implants is difficult. I have seen better and easier results with the N1 system, firstly because it has a trioval neck, which reduces stress on cortical bone. Secondly, the torque of the OsseoShaper drill correlates with implant torque, which guides the surgical workflow for predictable stability.

On the other hand, in the lower arch where the bone is denser, it is important not to over-compress during implant insertion, so as not to cause osteonecrosis and thus bone resorption. Here, the N1 implant design makes a difference, as its coronal and apical shape promotes distance osteogenesis and reduces the stress in bone, to ensure faster osseointegration.



## Would you say that the Nobel Biocare N1 system is for all situations?

I believe Nobel Biocare N1 is a versatile system that can be used in different situations, making it possible to safely treat patients with poor-quality bone such as those treated with bisphosphonate therapy or cancer patients who have undergone chemotherapy or radiotherapy. Furthermore, the new Xeal abutment surface provides a safe and stable soft tissue integration. I have seen this in my cases with three years of follow-up. Marginal bone remodeling has been minimal and the level of peri-implant soft tissue around Multi-unit Abutment Xeal has remained stable over time.



## How do you ensure a successful All-on-4® treatment?

One key to success is adhering to surgical and prosthetic protocols, which have been developed over the past 25 years and refined in every aspect to achieve the best possible outcomes in all clinical situations. The second is using high-quality materials and genuine components in both the surgical and restorative phases, as they have been specifically designed to ensure the long-term success of these types of rehabilitation procedures.



Smile of the patient after final rehabilitation

**"Whenever an innovation can improve patient outcomes, I believe we should take it into consideration."**



**Dr. Ana Ferro**  
Portugal

**After graduating from the University of Lisbon in 2004, Ana Ferro joined the MALO CLINIC team. Since then, she has treated hundreds of patients with the All-on-4® treatment concept, and has conducted numerous clinical studies focused on the Immediate Function of implants, periodontology, oral surgery, and dental implant rehabilitation.**

**Reference**

1. Ferro A, et al. Clin Oral Implant Research 2021; 32(S22):59.

**You have years of experience in the All-on-4® treatment concept. Dr. Ferro, what makes it particularly unique?**

In terms of medical approach, surgery, and prosthetics, All-on-4® is a straightforward procedure. Especially when it is compared to grafting, or placing many implants. One can learn it. However, the innovation of All-on-4® was the most important breakthrough in oral surgery, making it possible to give a fixed prosthesis to edentulous patients or patients with failing dentition in just one day. This makes it an amazing concept. With all the patient comfort, and the fact that they don't have to go through multiple surgeries, especially when they have systematic diseases, or when they are not the right fit for complex grafting procedures.

**You are conducting a clinical study with All-on-4® using NobelParallel™ CC implants and TiUltra™ and Xeal™ surfaces. What does this work investigate?**

The aim of this study is to evaluate how the new implant and abutment surfaces behave in terms of the survival rate of the implant, the biological behavior, and hard and soft tissue responses.

We started the study in 2019. But after a few patient enrolments, we were hit by the COVID pandemic and had to stop. That's why we could only finish the patient enrolment (n=40) at the end of 2021. So far, we have published the interim results, with a smaller group of patients (n=16), after 1 year of follow-up.<sup>1</sup>

---

***"The ability to actually change the patients' lives in one day with the All-on-4® treatment concept also changed my life as a dentist."***

---

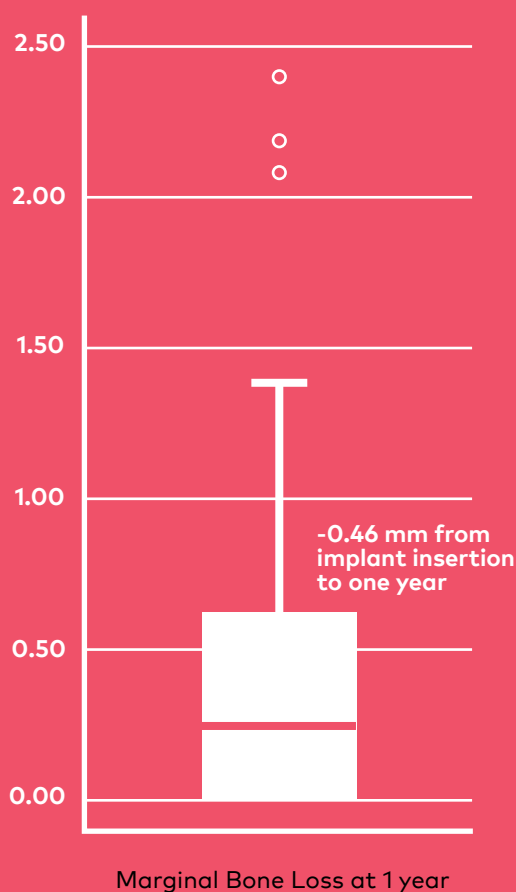
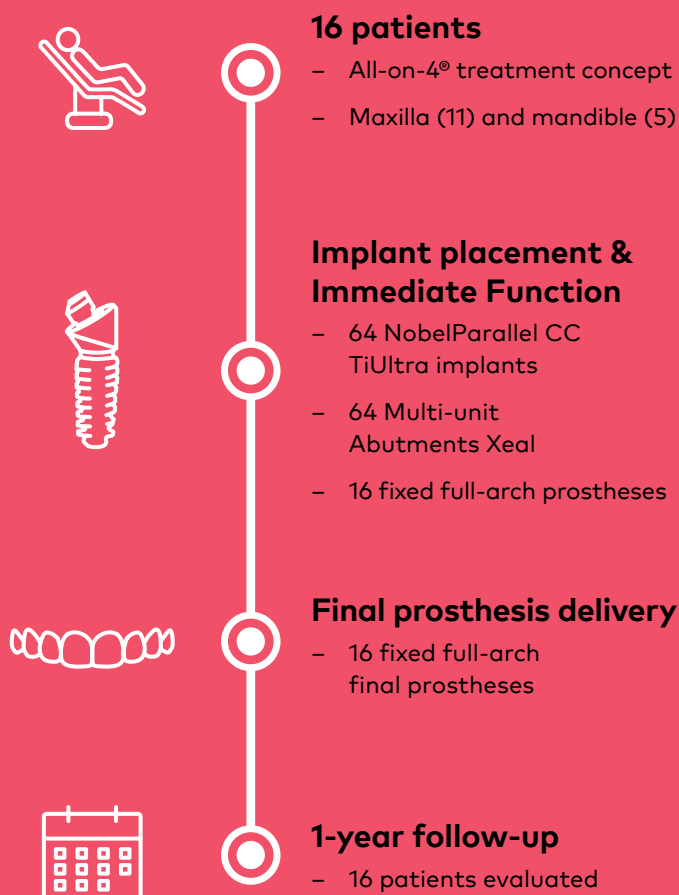
## What were your key results?

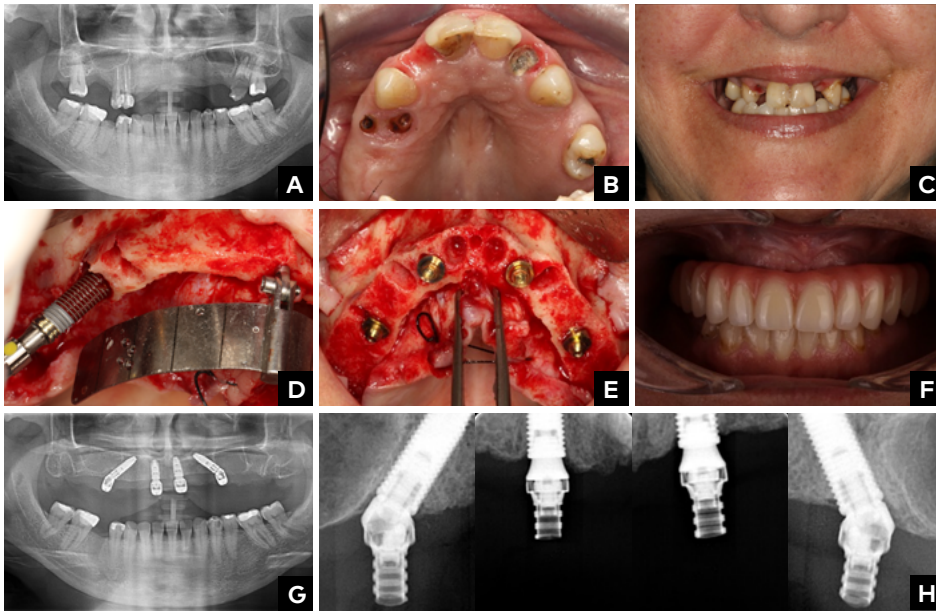
We achieved 100% implant survival rate for both implant and abutment with a mean marginal bone loss of just 0.46 mm after one year. Though some mechanical complications occurred with provisional-prosthesis screw fractures, there were no biological complications and a good and stable soft tissue response. In a nutshell, these are good results. And this is what we want for our patients - high success rate, good esthetics, predictability, safety.

## Did you use only NobelParallel CC implants in the study?

Yes. I usually use NobelParallel CC when I have minimal to medium resorption, and I can benefit from the TiUltra and Xeal new surfaces. However, depending on the quality and quantity of bone, and in an atrophic jaw, I may choose to work with other implant lines such as NobelZygoma™ or NobelSpeedy®.

# 100% cumulative implant survival and prosthetic success.





Images courtesy of Dr. Ana Ferro

**A/E** A 46-year-old female patient, smoker, with failing dentition and a high smile line was treated according to the All-on-4<sup>®</sup> treatment concept with four NobelParallel CC TiUltra implants and Multi-unit Abutments Xeal. **F** Patient received all-acrylic bridge 2 hours after surgery. **G/H** Analysis of OPG at 1-year, and X-rays at 3-year follow-up show excellent peri-implant bone stability.



Patient smile after surgery.

## What are the main benefits of TiUltra and Xeal surfaces for the All-on-4® treatment concept?

The fact that not only the implant but also the abutment surface is modified is crucial from an All-on-4® treatment perspective. The area between the abutment and implant is the "sacred zone" of All-on-4® — and the success of treatment is heavily dependent on staying at the abutment level.

TiUltra promotes osseointegration, and with the Multi-unit Abutments featuring Xeal surface, I can achieve better soft tissue response.<sup>2</sup> I truly believe, whenever an innovation can improve patient outcomes, we should take it into consideration.

## You advocate the importance of teamwork. How do you orchestrate this within your dental team?

I believe All-on-4® is not only a surgical concept. It is a team concept, starting from the patient, when they trust and accept our offering. Then it comes to implant surgeons, prosthodontists, dental technicians, and dental hygienists. We have strict protocols for all the steps to be done, and how to follow up. When the patient receives All-on-4®, it is only the start. If all goes well, they don't see me again and don't need me anymore. However, the team continues to take care of the patient for all their life through regular hygiene visits and controls. We make sure our team is calibrated and connected by diligently following our strict protocols for surgery, immediate prosthesis, final prosthesis, oral hygiene appointments, and what to do the day before surgery, after surgery, and later.

In this way, no matter who is the surgeon, prosthodontist, and oral hygienist, the results stay the same and predictable. This is what the patients deserve.

## Dr. Ferro, you publish scientific articles, lecture on international stages, work full-time in the clinic, and more. Which activity makes you the happiest?

Being able to help others! My patients come first. But also, with my peers, I love to contribute to knowledge sharing. I am a board member of two associations: the Professionals in Dentistry Esthetic Group (PiD-EG), which provides female dentists and dental students with tailored education programs and other networking opportunities to help them grow into more confident professionals. The second is the Foundation for Oral Rehabilitation, whose mission is to improve the quality of treatment available to oral healthcare providers. I am co-chair of the FOR Emerging Leader Program, which focuses on developing an international network of recognized professionals in the field.

However, the most rewarding time and what makes me the happiest is the time I can spend with my family.



Professionals in Dentistry (PiD-EG) meeting in Mahwah, USA, December 2021.



FOR

Watch the patient case presented at Envista Summit in Madrid [link](#)

### Reference

2. Hall J, et al. Clin Implant Dent Relat Res 2019;21(Suppl 1):55-68.

# What motivates the All-on-4® Centers of Excellence?

The All-on-4® Center of Excellence is a recognition given by Nobel Biocare to practices that demonstrate high expertise and experience in the All-on-4® treatment concept.

They also show commitment to success by using original-on-original components for quality that is greater than the sum of its parts.

All-on-4® Centers of Excellence are proud to put their award on show, but this program is much more than a trophy. They are part of the growing dental community that has events and courses to continue developing their skills and networks, and gain access to resources that enhance communication with their patients.

A program which first originated in Germany, it has expanded to recognize clinics in 26 countries and is growing across North America, Asia, Europe and Australia.



All-on-4® is amazing because it's immediate. Because it brings back function. Because you can personalize life-changing treatment for every single patient.

**Dr. Joe Mehranfar,**  
US



Longevity, strength, and esthetics. These are what I need for my patients, and I have been using exclusively Nobel Biocare to achieve this with the All-on-4® concept.

**Dr. Scott MacLean,**  
Canada



As a lab, we are continually seeing All-on-4® as one of the best decisions to make for health, immediacy, and long-term success.

**CDT. Greg Sederlin,**  
US




All-on-4® tackles some of the most challenging cases but they are the most rewarding. Our motto is "Experience excellence", and we are delighted to be recognized with this award

**Dr. Herlin Dyal,**  
US



Becoming an All-on-4® Center of Excellence is a milestone for us. It is a prestigious recognition and a great motivation to continue, knowing that our specialist work improves patients' lives by restoring lost function and esthetics with the best technology.

**Dr. Ignacio Ginebreda Cairó,**  
Spain



The All-on-4® treatment concept is one of the most powerful, versatile and predictable features in the implantology arsenal.

**Dr. Ernesto Tocantins,**  
Portugal



The unique design of NobelActive implants allows immediate loading with All-on-4® even with unfavorable bone conditions in the maxilla.

**Dr. Roberto Sleiter, Switzerland**



All-on-4® brings the possibility to realize a fixed full-arch rehabilitation in one day for patients with hopeless teeth, unstable dentures or even complete edentulism. Esthetics and function in such a short time brings back well-being and joy of life.

**Dr. Helmut Baader, Germany**



Innovation and precision are key elements in providing our patients with the improved quality of life they are seeking with the All-on-4® treatment concept.

**Dr. Chun-Yin Lee, Taiwan**



To become an All-on-4® Center of Excellence is a great honor, and helps reassure our patients in need of full-arch rehabilitation that we perform treatment to the highest standard and have a history of success.

**Dr. David Norcross, Australia**

Above all, the Center of Excellence program recognizes the tremendous services for patients over the last 25 years.

**Dr. Frédéric Philippart, France**

We have improved the quality of life of hundreds of patients with this extremely reliable solution, even in difficult cases. I thank Nobel Biocare for your All-on-4® expertise, and patients for your trust in me.

**Dr. Giampaolo Zanotto, Italy**

All-on-4® is evolving continuously. It has been inspiring to see this happen for 25 years, and I am very happy to become a member of the Center of Excellence community.

**Dr. James Chow, Hong Kong**



We always promise our patients the best quality of dental care, and that's why we use Nobel Biocare.

**Dr. Majd Najj, UAE**

# From failing dentition to a confident smile, in just one day



**Dr. Roberto Sleiter**  
Switzerland

**In real-world practice, surgical protocols and restorations should be tailored to the patient's needs, and thoroughly communicated. The time we dedicate to patient communication makes a big difference in satisfaction and compliance in the long run.**

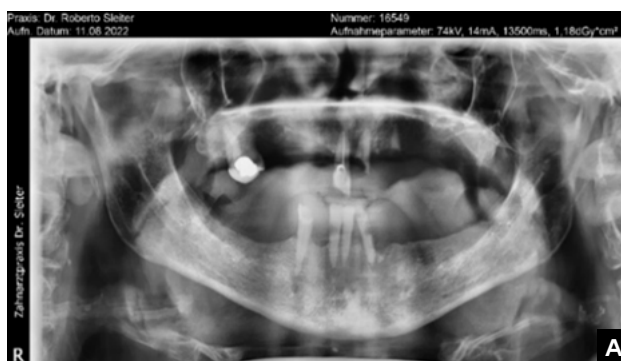## Clinical situation

In November 2022, a 71-year-old male patient came to our practice. He was looking for help with his oral health issues and hoped to improve his esthetics, as well as to have fixed functional dentures. He had been experiencing difficulty with his upper and lower removable dentures, which had negatively impacted his quality of life.

## Treatment planning

We examined the condition of the patient's jaw. He had residual dentition in both jaws with a severely compromised and esthetically unpleasing periodontal condition.

We chose the All-on-4® treatment concept for both jaws based on the anatomy of the remaining bone.



**A** Orthopantomogram (OPG) before treatment shows moderate-to-severe ridge resorption in both jaws.

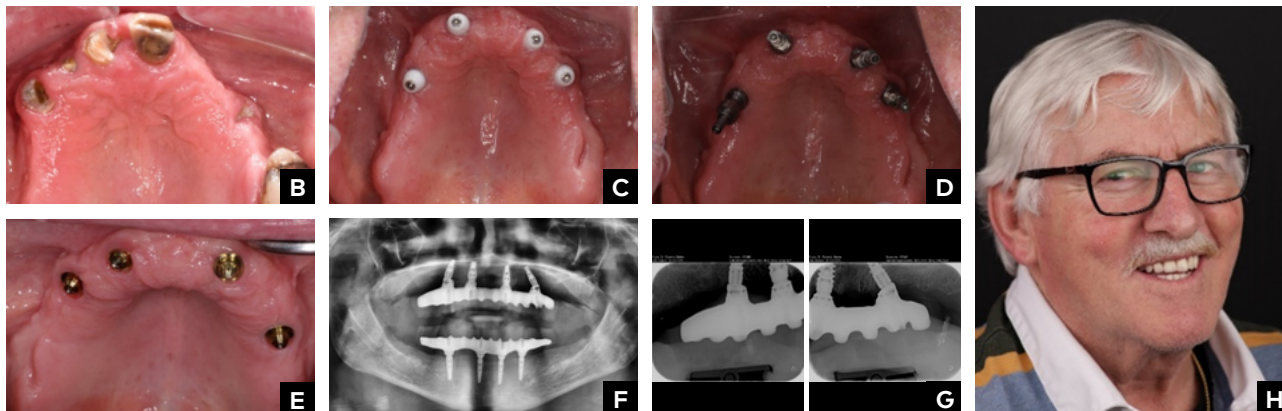
## Surgical solution

Surgery was performed a few days later. We extracted the hopeless teeth and placed the implants and Multi-unit Abutments according to the standard protocol of the All-on-4® treatment concept.



## Choosing implants based on bone quality

We used NobelActive® TiUltra in the maxilla in order to achieve high primary stability in the soft bone and Immediate Function. Also, we chose NobelReplace® TiUltra in denser mandibular bone, as its tapered body prevents the generation of excessive stress during insertion. Both NobelActive and NobelReplace implants are suitable for demanding situations that require immediate implant placement and function.<sup>1-3</sup>



**B** Intraoral view of the upper jaw before treatment. **C** Occlusal view of healing caps to save space in the maxilla. **D** Occlusal view of the impression copings in situ. **E** Multi-unit Abutments Xeal 6 months after surgery. Note the healthy soft tissue before delivery of the final prosthesis. **F** OPG showing the stable peri-implant bone level at the time of final prosthetic delivery. **G** Periapical radiography showing the fully seated definitive prosthesis and stable bone level 6 months post-op. **H** Patient's smile after receiving the provisional prosthesis.

## Patient-centric care

Complex dental problems and corresponding solutions are as individual as the patients themselves. We communicated every step of the process to the patient and used 3D images and digital tools to explain the final results, to ensure that treatment acceptance was a well-informed decision, truly based on his expectations and desired outcomes.

Patients always appreciate the opportunity to discuss their concerns and questions with the team. I have also experienced that informing the patient that we are an All-on-4® Center of Excellence using only premium solutions, backed by extensive clinical science, wins their complete trust. It helps keeping them engaged and compliant, including their commitment to a dental hygiene program and regular check-ups, to ensure excellent long-lasting clinical outcomes.<sup>2</sup>



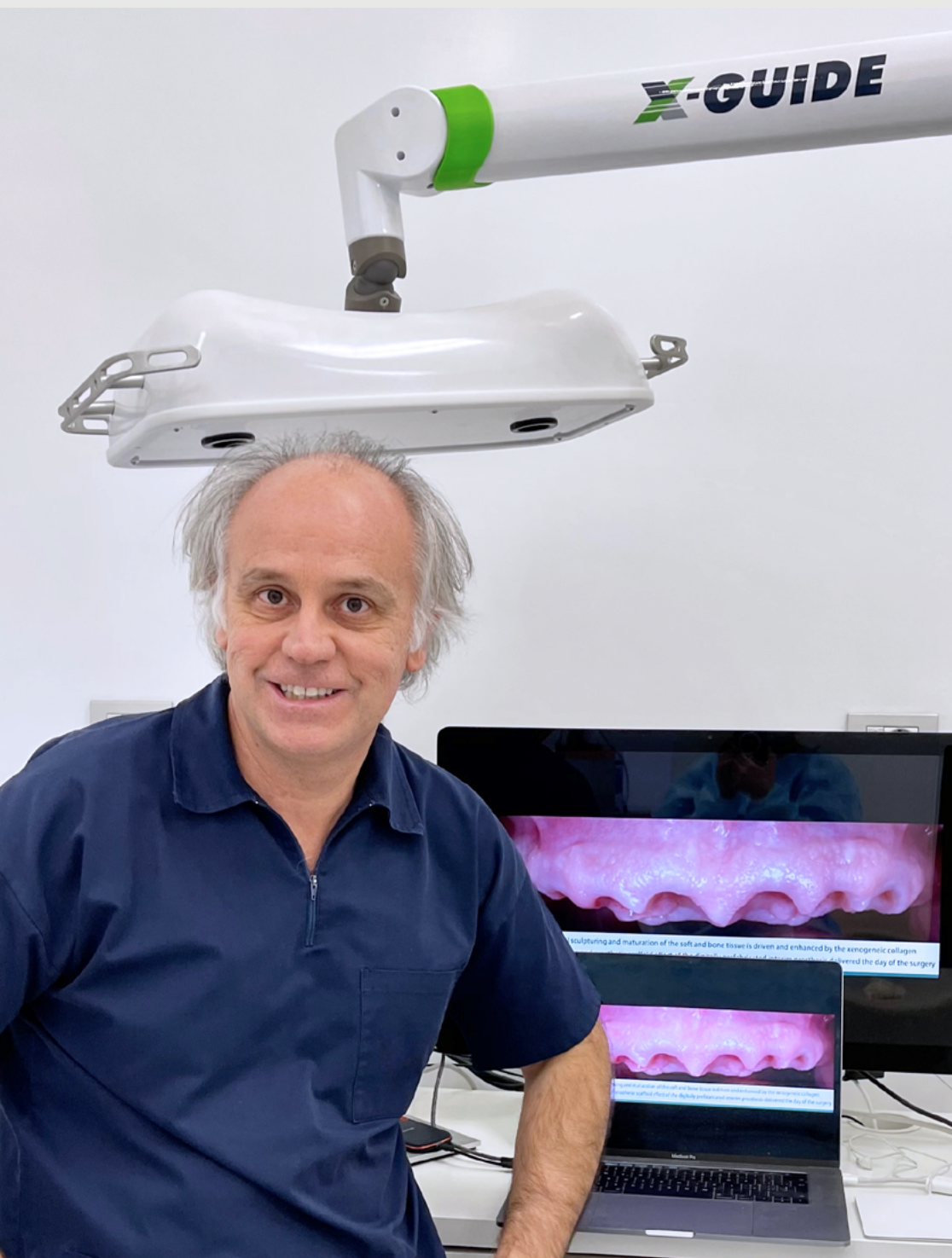Digital and visual communication tools make patient-clinician communication simpler than ever.

### Reference

1. Kolinski ML, et al. J Periodontol 2014;85(3):386-394.
2. Todisco M, et al. Oral Implantol 2018;11(3):169-76.
3. Pozzi A, et al. Eur J Oral Implantol 2015;8(1):51-63.

"After 20 years of successful computer-assisted surgeries, X-Guide® changed my work completely. It addresses the limitations of static guided surgery physical templates, which obstruct the view and management of the surgical field. Dynamic navigation brings my freehand surgery to the next level in terms of clinical accuracy, real-time control of potential intraoperative complications and, at the same time, extends the boundaries of digital minimal invasiveness without neglecting the fundamentals of implant dentistry. X-Guide® is a breakthrough approach that raises the level of care for our implant patients."

**Prof. Alessandro Pozzi, Italy**



**Guided or navigated surgery? Today's digital technology**

# "X-Guide® has made the full-arch treatment very precise and predictable."



**Dr. Marko Kamel**  
USA



**Katie Lank**  
Switzerland

Freehand surgery with real-time 3D guidance of your drills and implants with X-Mark turns your diagnostic scan into a navigated plan. X-Guide is 3-4 times more accurate than other dynamic systems tested.<sup>1</sup>

## **Dr. Kamel, how has X-Guide® changed your All-on-4® treatment concept workflow?**

With the truly 100% digital workflow, X-Guide has made the full-arch treatment very precise and predictable.<sup>1,3</sup> In a very resorbed ridge, a freehand technique or static guided systems are less predictable, while the advanced design of X-Guide gives me the real assurance in ideal bone positioning, so that every patient receives the best possible treatment. Furthermore, it gives us the chance to accept referrals from other providers in our area because they lack the level of precision we can provide with X-Guide.

## **Have you seen any differences in clinical outcomes since adopting dynamic navigation?**

We now are having fewer problems with the implant integration and have patients seeking our office services after being sent away by other clinics.

## **What do you want your patients to know about the technologies you choose to use for their treatment?**

That we can provide them with surgeries that are less traumatic due to no incision and no sutures, less swelling, and more precision using computer programming systems. They know that they are getting the best treatment option for the same price of regular implant placement with but with a lower risk of complication.

**Ms. Lank, you are a biomedical engineer and worked on verification and validation of X-Guide before joining Nobel Biocare. In simple terms, how does the system work?**

X-Guide offers interactive, turn-by-turn guidance during surgery for more exact implant placement – like GPS for your drill. It does this by tracking the position of both the surgical handpiece and the patient in real-time synergy via two cameras that are positioned 60-80 cm above the patient. There is no need for a surgical template. Using the treatment plan on the patient's cone beam CT, X-Guide can help dentists confidently place implants where they planned them.


It's amazing to see how the product has evolved since I left X-Nav Technologies back in 2016. X-Nav's leadership team includes part of the original team that disrupted dentistry with the i-CAT® cone beam CT. I think it's safe to say that they are in the midst of disrupting the market once again, which isn't easy to do.

**What do scientific studies tell us about the accuracy of navigated dental surgery?**

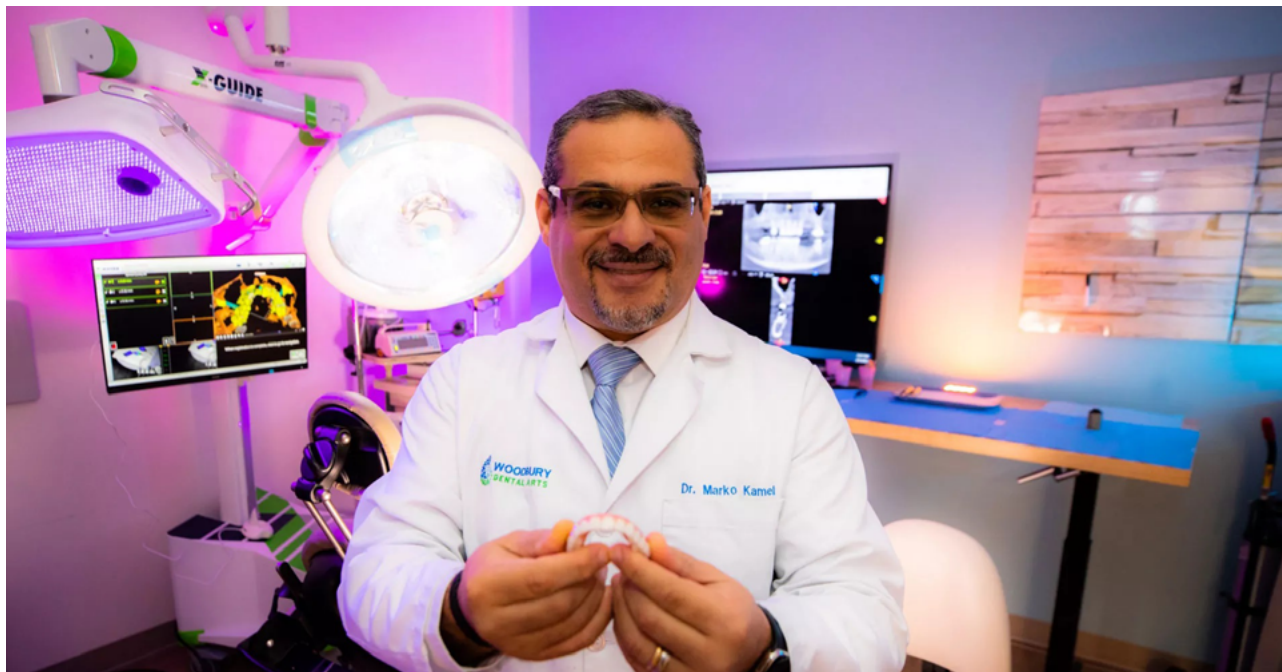Several studies show the improved accuracy of navigated surgery compared to freehand surgery, including some meta-analyses.

One notable study was a prospective clinical study with over 714 implants, of which 592 were guided, and 122 freehand.<sup>4</sup> It showed that the accuracy of X-Guide is similar to static CT-generated guides, and that there is a statistically significant improvement in accuracy compared to freehand implant placement. The accuracy improvement is most significant for angular accuracy, with navigated surgery being 11 times more accurate than freehand surgery. Overall, accuracy of navigated surgery is five times more accurate than freehand.

Like any new technology, there is a learning curve. This was also documented in a clinical study that compared accuracy results from three experienced surgeons over time.<sup>3</sup> After 20 implants, all three surgeons showed comparable accuracy results using navigation.



X-Guide offers interactive, turn-by-turn guidance during surgery for more exact implant placement – like GPS for your drill.



With X-Guide, you have predictability and start with the end results in mind.

### **Dr. Kamel, what was your learning curve to fully adopting navigation?**

Learning and adapting to the technology was quite straightforward. It may take a bit of time to get used to looking at the screen instead of looking inside the mouth, however this has been very ergonomic for me as I am not bent over all the time. Today, we use X-Guide for every case – even with immediate implant after extraction – because we measure twice and cut only once.

### **What would you tell someone who doesn't know about X-Guide navigated surgery yet?**

With X-Guide, you have predictability and start with the end results in mind.

### **You offer a training center for other surgeons to learn about digital techniques for implant surgery.**

Yes. At the Smile Rescue Academy we teach the step-by-step technique of using X-Guide for full-arch treatment to dentists from all over the world. We also show them the restorative option of using digital workflows on designing the restoration and delivering it the same day.

### **When using X-Guide, what is the benefit to the restorative part of implant treatment?**

Pre-planning of the restoration, especially on the single implant cases in the anterior, provides us with guidance on which Multi-unit Abutment to use as well as the difference between the bone available versus the tooth position, so we do not end up with an implant that cannot be restored, which we have seen at some other clinics.

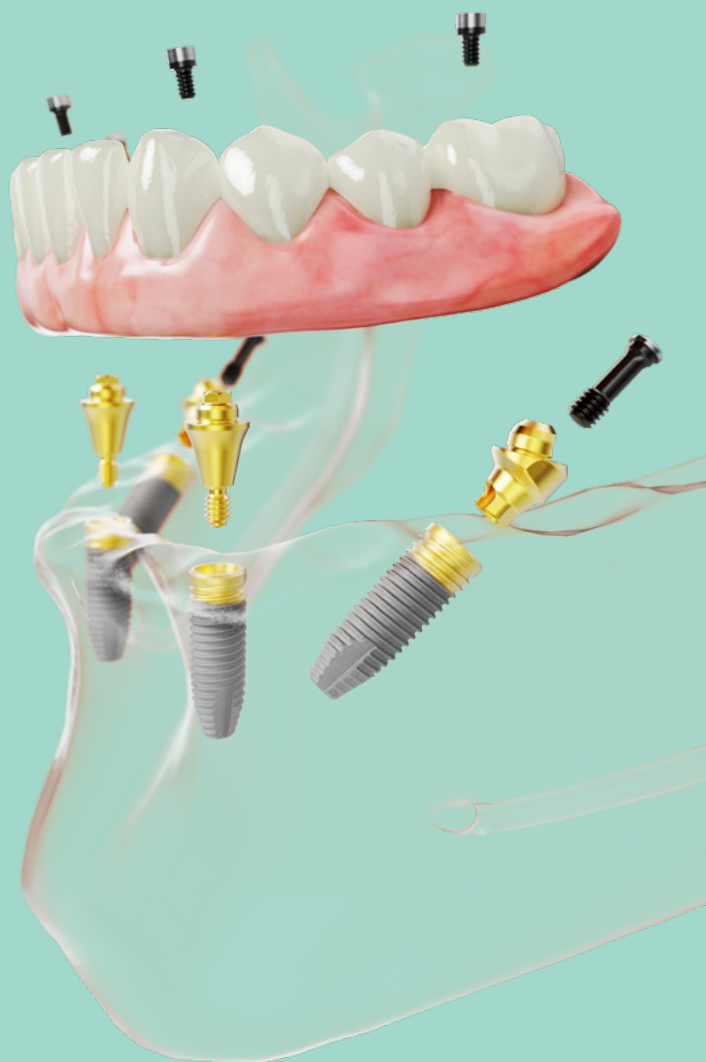
### **Where do you see this technology going in the next 3-5 years?**

I think X-Guide could be used for more dental procedures. We even started implementing it in bone reduction, bone expansion and bone block manifestation.

#### **Reference**

1. Emery RW, Merritt SA, et al. J Oral Implantol. 2016;42(5):399-405.
2. Pozzi A, et al. J Esthet Restor Dent. 2021;33(1):224-236.
3. Block MS, et al. Int J Oral Maxillofac Implants. 2017;32(1):92-99
4. Block MS, et al. J Oral Maxillofac Surg. 2017;75:1377-1386.

# Multi-unit Abutments: Key to the All-on-4® treatment concept<sup>1</sup>


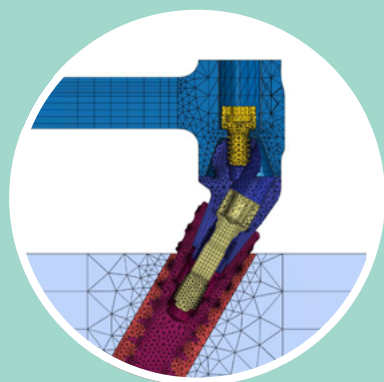


## Answering a clinical need

Nobel Biocare Multi-unit Abutments enabled the restoration of teeth using tilted implant placement. Developed in 2000, they were the first of their kind. They are now widely accepted as an industry standard.

## Precision engineering

What sets the Multi-unit Abutment apart from the rest are the design details, which can make or break a restoration. To this day, it is still the only one of its kind with a patented handle for a supreme handling experience.



## Nobel Biocare continues to set the standards of patient care

Introducing the snap function in 2016 simplified the temporization workflow. It also reduced the chair and lab time, while the fatigue strength increased by 25%.<sup>2</sup>

### Reference

1. Maló P, et al. Clin Implant Dent Relat Res. 2019;21(4):565-577.
2. Data of file
3. Hall J, Neilands J, Davies JR, et al. Clin Implant Dent Relat Res. 2019;21 Suppl 1:55-68.
4. Ferro A, De Araújo Nobre M. Clin Oral Implant Research 2021; 32(S22):59

## Backed by 20+ years of evidence

The clinical predictability of Nobel Biocare's multi-unit abutments has been documented in at least 125 clinical studies.<sup>2</sup>



"Anatomical conditions often prevent placement of dental implants in a perfectly parallel orientation. This, together with the variable depth of implant placement and differences in soft tissue thickness, can make it difficult to verify the tightness of the connection between the screw-retained prosthetic restoration and the implant at the implant level. The resulting micro-gaps can cause inflammation and lead to excessive marginal bone loss. But the use of Multi-unit Abutments transfers the connection with the screw-retained prosthetic restoration above the soft tissues.

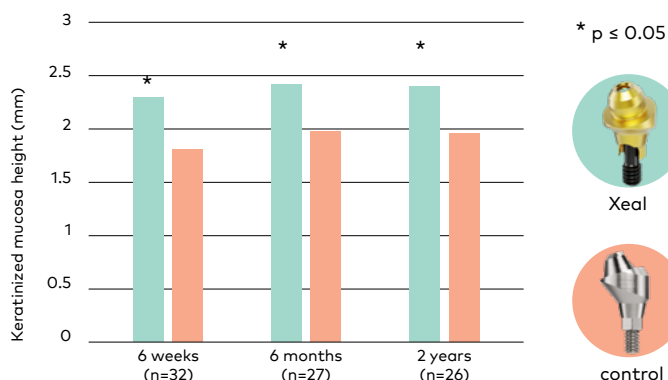
Based on my experience, the use of Nobel Biocare Multi-unit Abutment can significantly decrease the occurrence of peri-implantitis. Additionally, it enhances patient comfort during prosthetic appointments, as the delicate soft tissues created around the abutment stay untouched. I believe the use of Multi-unit Abutments should be a standard for implant-supported restorations on three or more implants."

**Dr. Marcin Graboń, Poland**

## Featuring Xeal™ since 2019. The pioneering Mucointegration™ surface

- The smooth, non-porous, and nanostructured surface of Xeal Multi-unit Abutment improved soft tissue healing and increased keratinized mucosa height in a randomized, controlled, clinical study.<sup>3</sup>
- Interim results of a prospective clinical study with All-on-4® treatment concept in 16 patients and 64 Multi-unit Abutments Xeal showed no biological complications and a healthy soft tissue response after 1 year.<sup>4</sup>

### Increased keratinized mucosa height at Xeal vs machined abutments.



# Successful 10-year outcomes of NobelProcera® restoration in hybrid All-on-4® treatment concept



**Dr. Armando Lopes**  
Portugal

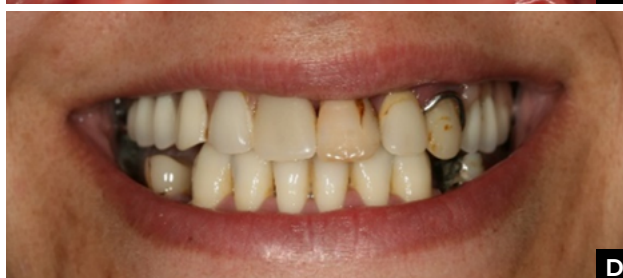
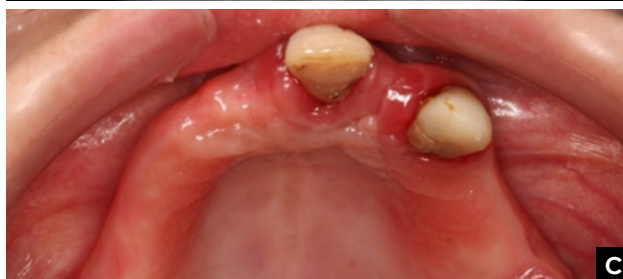
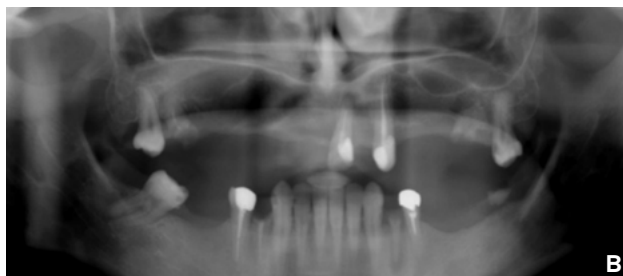**Dr. Carlos Moura Guedes**  
Portugal

## Clinical situation

A 34-year-old healthy female patient visited Malo Clinic Lisbon in October 2012 with the goal of having fixed teeth in the maxilla. She had been using an upper removable denture for more than 15 years and was uncomfortable and unhappy with this situation. She found the clinic through Portuguese media and television programs.

After clinical and radiographic examination, atrophic maxilla with failing dentition was diagnosed.



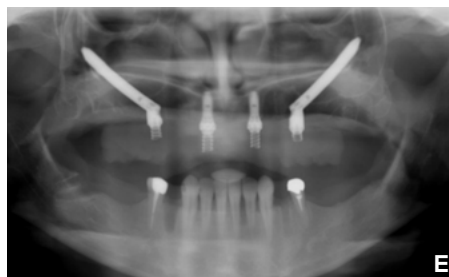
**A** Initial extraoral photo without dentures, in a maximum smile. **B** Orthopantomogram. **C** Initial intraoral maxilla occlusal view. **D** extraoral photo with denture at maximum smile.



## Treatment plan and surgical procedure

Cone beam computed tomography (CBCT) scans showed bone volume of less than 5 mm width by 10 mm height between the inter canine area. Due to extensive alveolar bone resorption, the standard All-on-4® treatment concept was not ideal. To avoid long and extensive bone augmentation procedures, we decided to use hybrid All-on-4® rehabilitation.

The surgery was performed in March 2013. After extracting the hopeless teeth and raising the flap, two NobelSpeedy Groovy NP 3.3 x 10 mm implants were placed in the anterior region of the maxilla (in the 12 and 22 positions). Two NobelZygoma 0° 5.0 x 40 mm implants were placed in the zygomatic bone (in the 15 and 25 positions) following the extra-maxilla technique.<sup>1</sup> All the implants reached 50 Ncm torque and two straight Multi-unit Abutments of 2 mm were tightened to 30 Ncm at the anterior implants. One 45° Multi-unit Abutment of 6 mm and one 45° Multi-unit Abutment of 8 mm were tightened to 30 Ncm each at the NobelZygoma implants. Five hours after surgery, the patient received a fixed screw-retained all-acrylic provisional 12-unit bridge crowns.

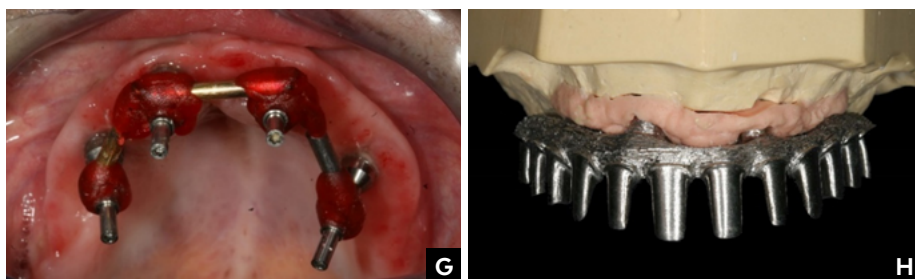


**E** Post-operative orthopantomogram. **F** Patient smile with provisional bridge two months post-op.

## Final bridge

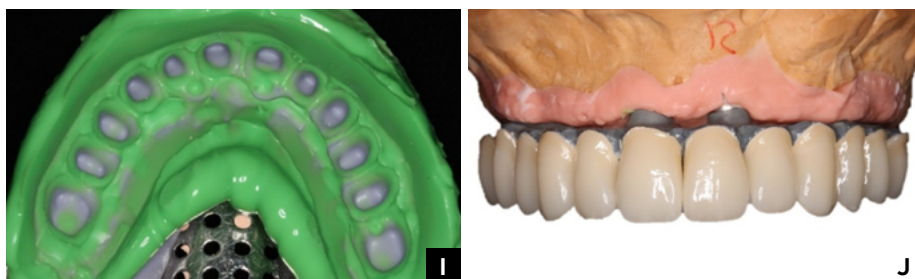
The final prosthetic procedure started four months after surgery. A definitive impression was taken in two steps: first, multi-unit impression copings and stainless-steel bars were splinted together with a low-contraction autopolymerizing acrylic resin, and second, a definitive impression was made with a custom open tray and addition reaction silicone impression material.

The dental laboratory used the tooth arrangement on the fixed screw-retained all-acrylic provisional bridge as a starting point to manufacture the definitive prosthesis. First, an acrylic resin screw-retained pattern of the provisional bridge was made on the master cast to plan the future titanium framework. This acrylic resin pattern was fabricated with 12 individual crown preparations to accommodate the corresponding individual ceramic crowns. After the pattern was completed, it was scanned and uploaded to the NobelProcera® software. The data were transferred digitally to a milling machine for the fabrication of a NobelProcera titanium framework.



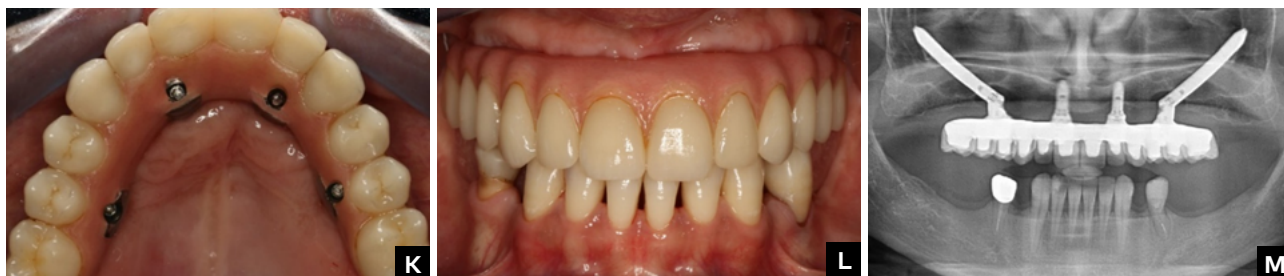**G** Maxilla definitive impression preparation with multi-unit impression copings splinted with stainless-steel bars. **H** NobelProcera titanium framework.

Once the titanium framework was milled, a silicone impression was made of the framework preparations. Twelve monolithic ceramic crowns were then fabricated and milled in lithium disilicate. After glazing, the crowns were cemented to the framework using a definitive cement, the screw access openings were opened, and the customized acrylic gingiva was applied and polymerized around the crowns and in the inferior portion of the prosthesis.<sup>2</sup>



**I** NobelProcera titanium framework silicone impression. **J** NobelProcera titanium framework with the ceramic crowns cemented.

The final bridge was delivered six months after surgery and the patient was enrolled in our clinic maintenance program, which includes regular semi-annual oral hygiene appointments and peri-implant soft tissue health and implant condition assessment.



**K** 10-year follow-up; occlusal view. **L** Frontal view. **M** Orthopantomogram.

## Key to success

The Immediate Function, which was highly appreciated by the patient, was enabled by the design of the NobelZygoma implants in the posterior, and the narrow diameter of the NobelSpeedy Groovy NP implant in the thin and resorbed anterior alveolar crest.

---

***"No other premium company offered an implant with the features of NobelZygoma 0° for immediate loading and 45° Multi-unit Abutment at the time this patient was treated."***

---

One other reason for the long-term success of this rehabilitation was the use of a high-quality final screw-retained ceramic bridge.<sup>2</sup> We achieved optimal esthetics by using 12 individual ceramic crowns which were fixed on a NobelProcera titanium framework. The passive fit and mechanical resistance of this framework allow for homogeneous distribution of loading to maintain the marginal bone around the implants and ensure 10 years of function without complications.



10 years after surgery.

### Reference

1. Maló P, et al. J Prosthet Dent. 2008;100(5):354-66.
2. Maló P, et al. J Prosthodont. 2012;21(4):256-64.

# A fully facial analysis-based guide to edentulous treatment



Dr. Ernest Orphanos  
USA

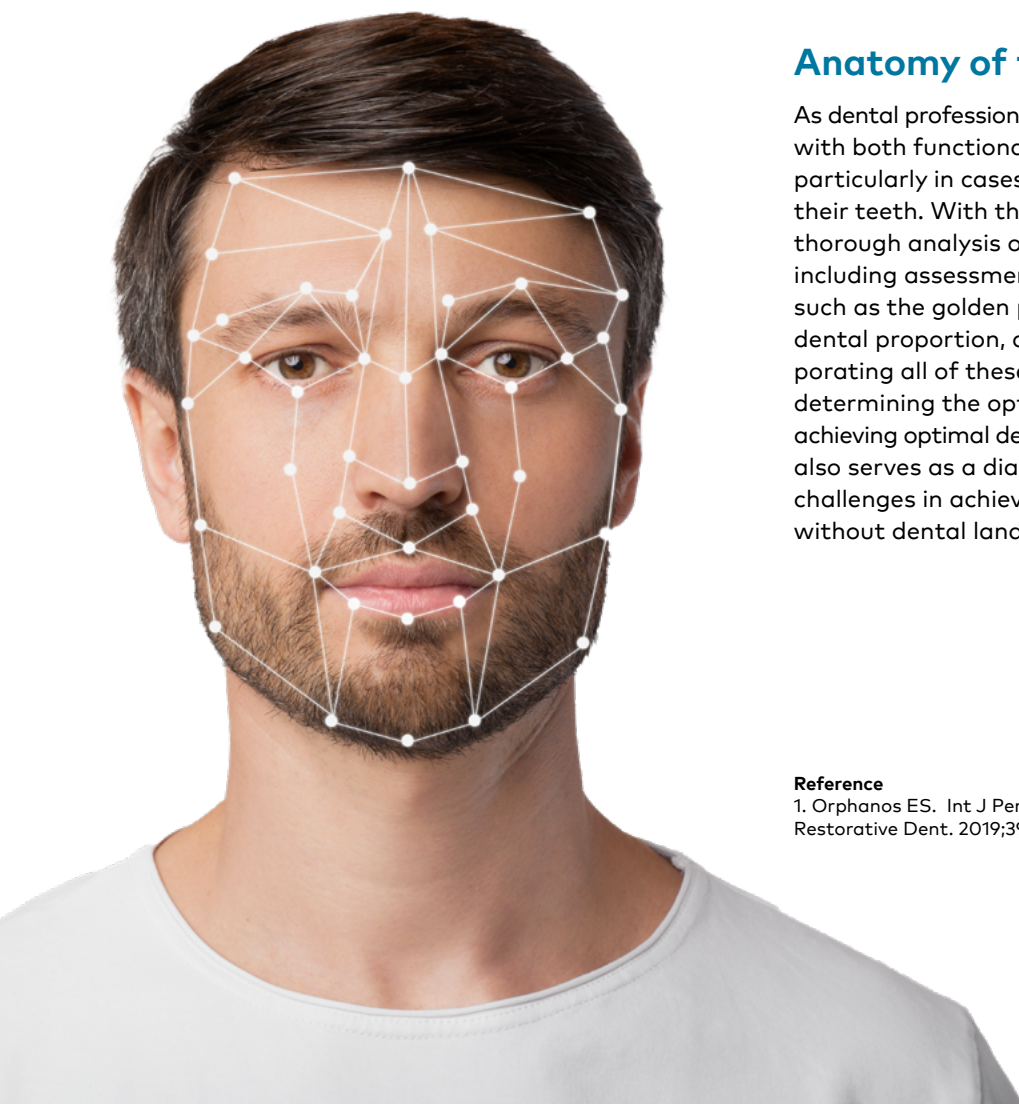
To improve the predictability of our patients' esthetics, treatment should be planned in a full facial context, not just that of oral anatomy. Without this consideration, even the most well-designed restoration risks disappointing esthetics.

## Anatomy of face and smile

As dental professionals, our goal is to provide patients with both functional and esthetically pleasing smiles, particularly in cases where patients have lost all of their teeth. With this goal in mind, we conduct a thorough analysis of the patient's facial anatomy, including assessments of various facial proportions such as the golden proportion, recurring esthetic dental proportion, and golden percentages.<sup>1</sup> Incorporating all of these facial proportions is critical in determining the optimal size and shape of teeth and achieving optimal dentofacial esthetics. This analysis also serves as a diagnostic tool to help address challenges in achieving an ideal tooth position without dental landmarks.

### Reference

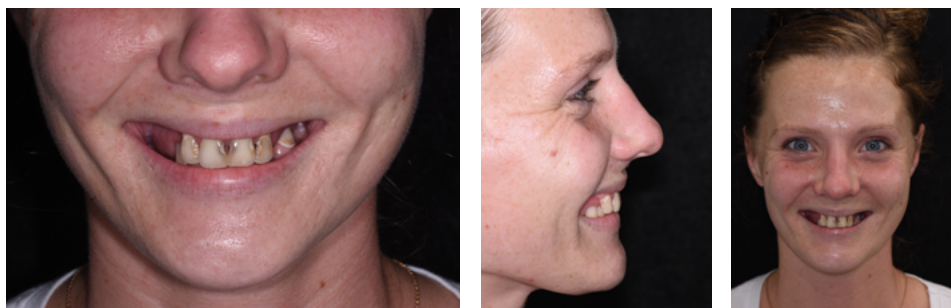1. Orphanos ES. Int J Periodontics Restorative Dent. 2019;39(1):57-64.



## Pre-operative assessment

A female patient with terminal dentition required full-arch restoration in both jaws. After cone beam scan and a periodontal and oral examination, she underwent an assessment of facial symmetry and proportions, including facial thirds, the proportion in the lower facial third, lip length, and lip mobility.

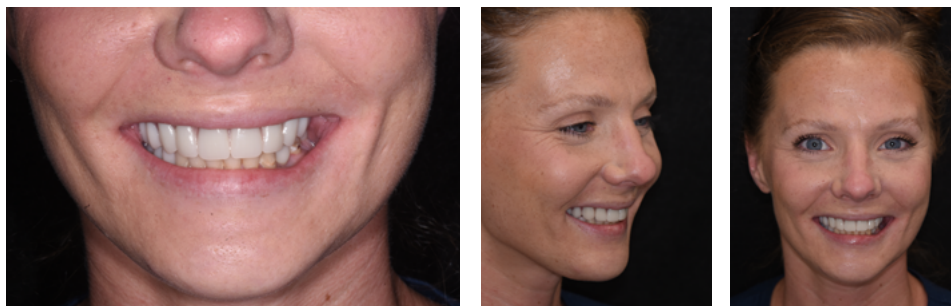Incorporating facial proportions is crucial for achieving ideal dentofacial esthetics and determining the anticipated incisal edge (AIE) position when planning for an esthetically pleasing smile. Ideally, the AIE position should show 1.0 to 2.0 mm at rest, with a repositioning of incisal edges apically by approximately 4.0 mm when smiling.



Periodontal examination and face analysis prior to surgery.

## Surgical Protocol

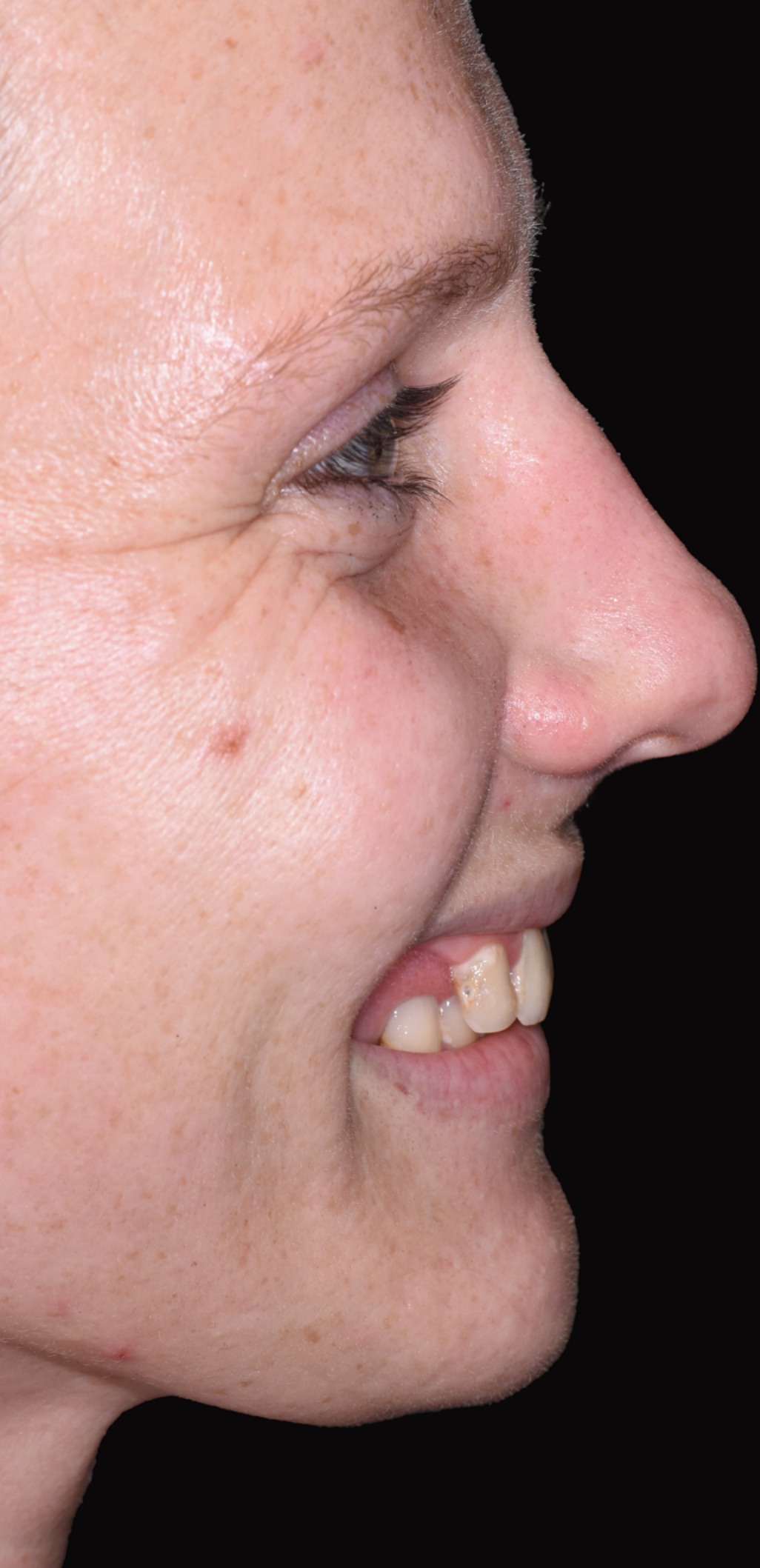The patient was treated with the All-on-4® concept in the mandible and full-arch on six implants in the maxilla. The maxillary ridge was reduced to ensure a minimum distance of 15.0 mm from the AIE, as determined from facial photos, to prevent the transition zone of the prosthesis from being visible during maximal smiling. Following alveolar reduction, a denture was fitted to evaluate proper facial support. After placement of implants, the patient received the provisional prostheses that produced a striking transformation in her appearance.



After delivery of provisional prostheses.

## Begin with the end in mind

The ultimate goal of full-arch treatment is to restore dental and facial esthetics, phonetics and function. An understanding of the facial anatomy can help clinicians determine optimal incisal position. This in turn can enhance the dental and facial outcomes.





Patient smile after delivery of final prostheses.

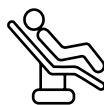# Proven long-term success in challenging situations: ten-year clinical outcomes<sup>1</sup>

## Aim

To investigate the outcomes of the All-on-4<sup>®</sup> treatment concept when implants are inserted in sites with dehiscence or fenestration

## Study design

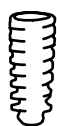Single cohort clinical study (patients retrospectively selected based on the presence of dehiscence or fenestrations).



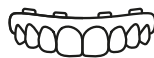**123**  
patients



**127**  
full-arch rehabilitations with the All-on-4<sup>®</sup> treatment concept



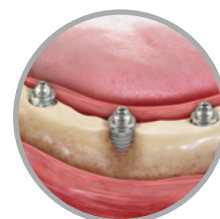
**192**  
Nobel Biocare implants  
Immediate Function



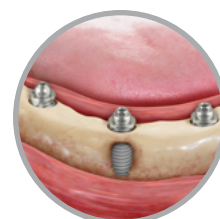
NobelProcera<sup>®</sup> titanium framework, and NobelProcera crown or acrylic resin teeth



**10-year**  
follow-up



**150 implants with dehiscence**  
Absence of alveolar bone and apical implant exposure



**40 implants with fenestration**  
Buccal or lingual window defect

**2 implants with both dehiscence and fenestration**

**Reference**  
1. de Araújo Nobre M, et al.: J Clin Med. 2022 31;11(7):1939



# Ten-year results

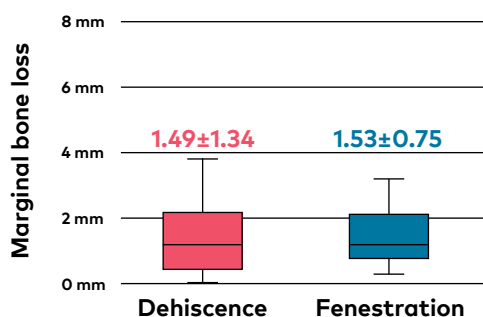
**96.2%** implant survival rate: 97.2% in the dehiscence and 90.0% in the fenestration group.

**98.4%** prosthetic survival rate: 98.9% in the dehiscence and 96.4% in the fenestration group.

**1.53±0.75** mm mean marginal bone loss.

18 of the 192 implants demonstrated biological complications: suppuration (n=2), infection (n=2), fistula (n=1), and peri-implant pathology (n=13).

## Marginal bone loss at 10 years



# Authors' conclusion

***"Implants inserted with dehiscence or fenestrations demonstrate good long-term outcomes with overall high success and survival rates and low average marginal bone resorption."***

# "With proper maintenance, complex cases can still be successful."



**Prof. Miguel de Araújo Nobre**  
Portugal

Should edentulous patients with challenging bone anatomy be treated with the All-on-4® treatment concept? We asked Prof. de Araújo Nobre, the first author of a recently published clinical study "The 10-Year Outcomes of Implants Inserted with Dehiscence or Fenestrations in the Rehabilitation of Completely Edentulous Jaws with the All-on-4 Concept."<sup>1</sup>

## **Prof. de Araújo Nobre, why did you and your team decide to conduct this study?**

At Research, Development and Education Department of Maló Clinic, we perform clinical research, and we have a saying, "Clinical research is real-life research" because we don't only include patients with excellent prognoses in our studies. It is normal to have patients seeking treatment that don't present perfect conditions for All-on-4® treatment concept rehabilitation, such as good bone volume and density, absence of smoking habits, or systemic conditions. In this study's sample, the large majority of patients presented health complications. Eventually, some complications may occur, and it was our objective to prove that with proper maintenance, complex cases can still be successful with at least a decade of follow-up. This, in turn, would enable more clinicians to either avoid complications or handle them correctly.

### **Reference**

1. de Araújo Nobre M, et al.: J Clin Med. 2022 31;11(7):1939

### **Did you use the standard All-on-4® treatment concept?**

We used the standard All-on-4® treatment concept in almost all cases. The only exceptions were implants with fenestrations in immediate extraction sockets. When the implant was exposed inside a socket, the autogenous bone graft obtained during the smoothing of the bone crest was condensed in the socket to hide the fenestration and prevent soft tissue migration.

### **How do you discuss the risk of complications with the patients?**

The risk of complications is always discussed with the patients during the treatment planning phase prior to surgery, so they can take an informed decision about their rehabilitation. Moreover, the surgical and maintenance teams are prepared before the procedures, to be ready for handling the complication – for example, the existence of pseudo-pockets during the maintenance phase of implants with dehiscence.

### **What was the rate of biological complications in this study?**

We registered an incidence of 9.4% at the implant level and 14% at the patient level, which is within the range that we expect and know from our long-term studies.

### **What are the most common complications at the prosthesis level?**

The most common mechanical complications are acrylic resin crown fracture and prosthetic/abutment screw loosening. These mainly occur in patients with both jaws rehabilitated and/or are heavy bruxers. For these patients, we recommend a strict recall regimen and at least annual prosthodontic appointment for evaluating the occlusion and the prostheses.

---

*Both bruxing habits and implant-supported prostheses as opposing dentition are well-documented risk factors for mechanical complications.*

---

### **Is there any standard of care when an implant in the All-on-4® treatment concept fails?**

It is rare that an implant for the All-on-4® treatment concept cannot be saved, but if it happens, we can insert a new implant after waiting for the bone to heal.

### **When is a surgeon skilled enough to consider treating compromised patients with the All-on-4® treatment concept?**

It is important that these cases are handled by experienced surgeons. Surgeons considering treating compromised patients should first seek training in one of the available All-on-4® High-skill surgical protocol courses.

# Where patient-centric innovations and clinical science meet



**Dr. Marjan Gilani**  
Switzerland

## Changing lives

In the early 1990s, Dr. Paulo Malo challenged the traditional methods of treating edentulous patients by introducing a groundbreaking innovation to the field of dental rehabilitation: immediate loading of a fixed full-arch prosthesis on just two straight and two tilted implants. The first edentulous patients were treated with what is called today, the All-on-4® treatment concept in 1990s. However, the dental community was not ready to accept this paradigm shift, and the inventor team had to wait several years before seeing their work in a peer-reviewed publication.<sup>1</sup> In their first retrospective clinical study with 44 patients, 176 immediately loaded Brånemark implants for the All-on-4® treatment concept were followed for 2 years and achieved cumulative survival rates of 96.7%. Since then, this innovation has become a standard practice in many dental clinics worldwide, providing patients with a predictable, and time- and cost-efficient treatment option.<sup>2</sup>

## Patient stays at the center

Edentulism is estimated to affect over 350 million people globally.<sup>3</sup> Implant-supported restorations are recognized as the optimal treatment solution for these patients.<sup>4</sup> But the All-on-4® treatment concept raises the bar of patient centricity, by making it possible to deliver a fixed dental prosthesis and improving their oral health-related quality of life in just one day. For an edentulous patient who might have been suffering from impaired masticatory function, social handicap, and poor quality of life, receiving a fixed provisional prosthesis on the same day as their surgery is a

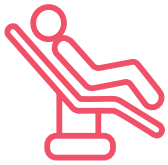transformative life experience. Patient-reported outcomes confirm the high degree of patient satisfaction with esthetics, phonetics, and function.<sup>5,6</sup>

But, is this solution delivered in one day predictable, too? Yes, as our science confirms. Today, the All-on-4® treatment concept is widely recognized as one of the most established solutions for edentulism, documented in more than 57 clinical studies, with over 24,300 anodized surface implants (TiUltra and TiUnite) in more than 4600 patients.<sup>7</sup>



57

Clinical studies



Patients

4,600



Implants

24,300

## Science matters

To the best of our knowledge, no other implant-supported clinical concept for treating fully edentulous patients has been backed by as many long-term clinical studies, systematic reviews, and meta-analyses, which are the highest-ranked types of evidence. Del Fabbro *et al.*'s comprehensive systematic review article is one of the most recent publications on this topic, to examine the efficacy of fixed full-arch prostheses supported by both axial and tilted implants.<sup>8</sup> Out of 24 clinical studies which met the inclusion criteria, only 6 reported treatment outcomes were with implants manufactured by companies other than Nobel Biocare—confirming the significant role Nobel Biocare has played to advance clinical studies in this field. With 2637 patients including 1464 maxillary and 1271 mandibular arches, followed for up to 18 years, the cumulative survival rate was 93.91%, for implants, and 99.31% for prostheses, and comparable in peri-implant bone response between the treated jaw.

## Tilting the implants

Tilting posterior implants allows improved engagement of the existing bone. But, what effect does this have on stress distribution within the implant and the surrounding peri-implant bone?

In the clinical setting, Krekmanov *et al.* were possibly the first who published on "tilting of posterior mandibular and maxillary implants for improved prosthesis support." Their analysis showed the distribution of load in tilted and non-tilted implants is comparable,<sup>9</sup> which was

later confirmed by finite element models,<sup>10,11</sup> and suggested the tilted implants may even decrease the bone stress, due to the decreased cantilever area.

Today, more studies confirm that angulation of posterior implants in All-on-4® does not affect implant survival or marginal bone loss,<sup>12,13</sup> based on results with up to 15 years of clinical follow-up.<sup>14</sup>

## A long-term view is crucial

The longest follow-up clinical study we know for the mandibular arch has indeed been published by Malo *et al.*<sup>15</sup> In their retrospective longitudinal study published in the *Journal of Clinical Implant Dentistry and Related Research* in 2019, authors followed 471 edentulous patients treated with the All-on-4<sup>®</sup> treatment concept for up to 18 years. 98.8% of the prostheses survived, and the implant survival rate was 93%. After 10 years, the marginal bone remodeling was -1.72 mm. In that same year, the team published the findings of yet another long-term clinical study, including 1072 patients treated with the All-on-4<sup>®</sup> treatment concept in the maxilla.<sup>16</sup> After up to 13 years of follow-up, the prosthetic success was 99.2%, and implant cumulative survival was 94.7%. For implants that completed the 10-year follow-up, the marginal bone remodeling was -1.67 mm.

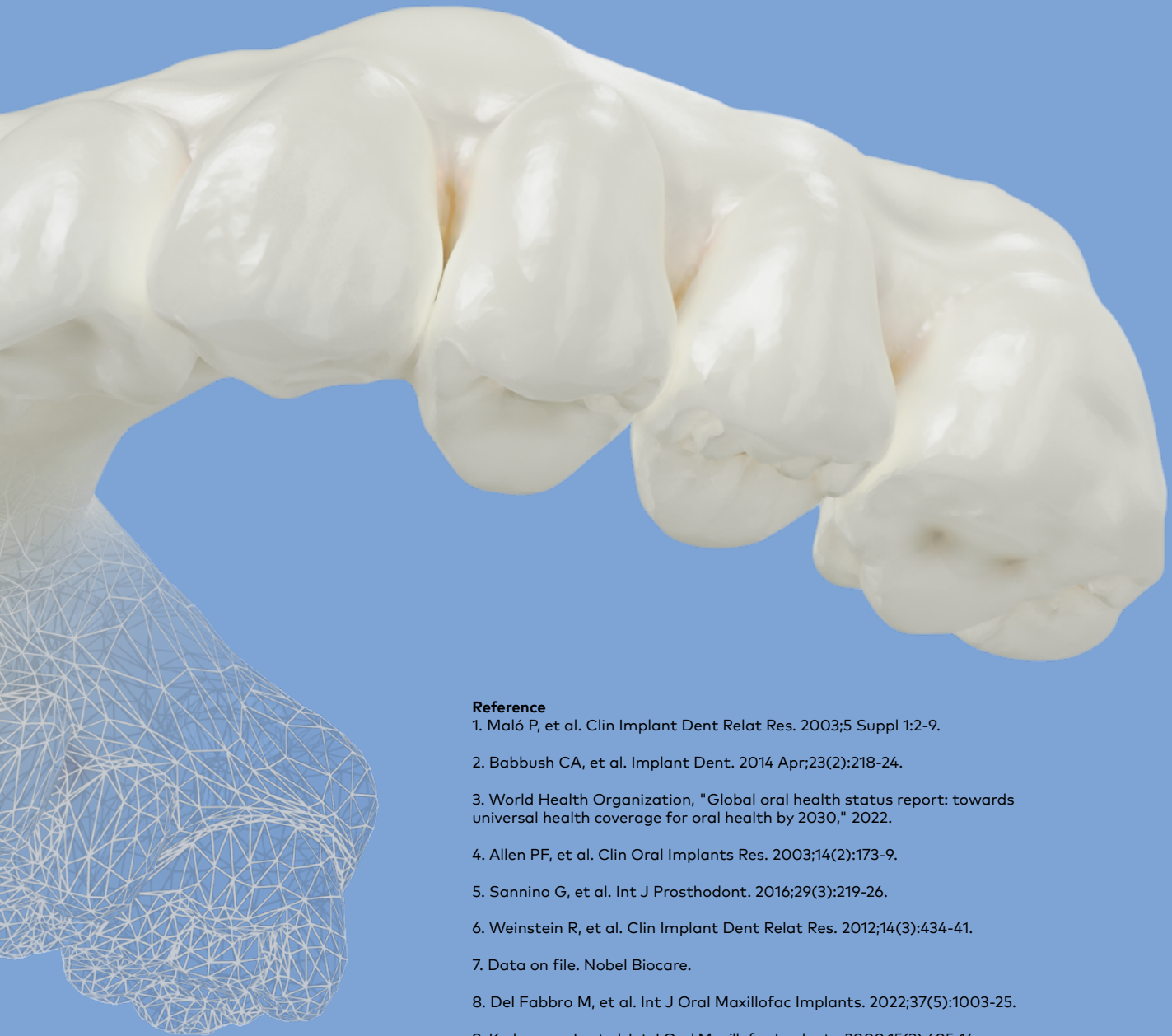Another recent publication featuring true long-term outcomes of the All-on-4<sup>®</sup> treatment concept is the retrospective study of Agliardi *et al.* with 692 Nobel Biocare implants placed in 72 maxillae and 101 mandibles. After up to 15 years of function, the implant cumulative survival rate was 97.5% in the maxilla, and 96.9% in the mandible.<sup>14</sup>

## Where our science is headed

Nobel Biocare has roots in science and clinical innovations. From believing in the young Paulo Malo in the early days of the All-on-4<sup>®</sup> treatment concept, to precision engineering, Immediate Function, digital dentistry, and now, introducing the era of Mucointegration™. The All-on-4<sup>®</sup> treatment concept with TiUltra™ implants and Xeal™ Multi-unit Abutments are currently being evaluated in several ongoing clinical trials, including a multicenter, prospective, non-interventional study with a total of 1000 patients in need of a single, multiple, or full-arch restoration<sup>17</sup>. Stay tuned and follow **#sciencefirst** on Nobel Biocare social media networks for information about the news on this study, and other real-world clinical evidence in dental implantology and regenerative science.

As said by Ralph Waldo Emerson, "**The mind, once stretched by a new idea, never returns to its original dimensions.**"





#### Reference

1. Maló P, et al. *Clin Implant Dent Relat Res*. 2003;5 Suppl 1:2-9.
2. Babbush CA, et al. *Implant Dent*. 2014 Apr;23(2):218-24.
3. World Health Organization, "Global oral health status report: towards universal health coverage for oral health by 2030," 2022.
4. Allen PF, et al. *Clin Oral Implants Res*. 2003;14(2):173-9.
5. Sannino G, et al. *Int J Prosthodont*. 2016;29(3):219-26.
6. Weinstein R, et al. *Clin Implant Dent Relat Res*. 2012;14(3):434-41.
7. Data on file. Nobel Biocare.
8. Del Fabbro M, et al. *Int J Oral Maxillofac Implants*. 2022;37(5):1003-25.
9. Krekmanov L, et al. *Int J Oral Maxillofac Implants*. 2000;15(3):405-14.
10. Huang HL, et al. *J Med Biol Eng*. 2022 42, 488–497.
11. Zampelis A, et al. *J Prosthet Dent*. 2007;97(6 Suppl):S35-43.
12. Chrcanovic BR, et al. *J Dent*. 2015 Feb;43(2):149-70.
13. Gaonkar SH, et al. *J Indian Prosthodont Soc*. 2021 Jan-Mar;21(1):3-10.
14. Agliardi EL, et al. *Clin Oral Implants Res*. 2023;34(4):351-366.
15. Maló P, et al. *Clin Implant Dent Relat Res*. 2019;21(4):565-77.
16. Maló P, et al. *Clin Implant Dent Relat Res*. 2019;21(4):538-49.
17. ClinicalTrials.gov Identifier: NCT04737421.



[nobelbiocare.com/allon4](https://nobelbiocare.com/allon4)



88981 GB 2308 © Nobel Biocare Services AG, 2023. All rights reserved. Nobel Biocare, the Nobel Biocare logotype and all other trademarks are, if nothing else is stated or is evident from the context in a certain case, trademarks of Nobel Biocare. Please refer to [nobelbiocare.com/trademarks](https://nobelbiocare.com/trademarks) for more information. Product images are not necessarily to scale. All product images are for illustration purposes only and may not be an exact representation of the product. Disclaimer: Some products may not be regulatory cleared/released for sale in all markets. Please contact the local Nobel Biocare sales office for current product assortment and availability. See Instructions For Use for full prescribing information, including indications, contraindications, warnings and precautions